

Midfoot Osteotomies for the Cavus Foot

Thomas W. Groner, DPM,
Lawrence A. DiDomenico, DPM, FACFAS*

*Department of Podiatric Surgery, Forum Health/Northside Medical Center, 500 Gypsy Lane,
Youngstown, OH 44501, USA*

Midfoot osteotomies have long been used for a wide variety of congenital and acquired deformities. These deformities include such entities as metatarsus adductus, clubfoot, arthritis, and pes cavus. Severe pes cavus often necessitates some form of midfoot osteotomy. In 1940, Cole popularized a dorsiflexory wedge osteotomy through the lesser tarsus to correct a cavus-type condition [1]. Japas later proposed a midfoot V-shaped osteotomy [2]. Through the years, several modifications and new techniques have been published. This article serves as an overview of documented and lesser-known techniques for the treatment of pes cavus with midfoot osteotomies. The etiology, evaluation, classification, and various treatments for pes cavus are also discussed.

Pes cavus

Pes cavus can be defined as an abnormal elevation of the medial longitudinal arch. Historically, the condition was synonymous with being born into nobility. Ancient Chinese culture used binding techniques to create shortened, high-arched feet [3]. In 1853, Little first coined the term “pes cavus” [4]. Presently, pes cavus is often secondary to a neuromuscular disorder and associated muscle imbalance. The condition may be classified as neuromuscular, congenital, idiopathic, or traumatic. A study by Brewerton reviewed 77 patients with pes cavus [5]. Three quarters of the patients were found to have an underlying neuromuscular condition, and congenital and idiopathic etiologies were reported at 14% and 11%

* Corresponding author.

E-mail address: ld5353@aol.com (L.A. DiDomenico).

respectively. The most common condition was Charcot-Marie-Tooth, followed by meningocele and poliomyelitis [5]. Numerous other etiologies may underly the cavus foot. These include diseases of the spinal cord such as tumors, syringomyelia, spinal muscular atrophy, and poliomyelitis [4,6,7]. Other neuromuscular conditions are muscular dystrophy, cerebral palsy, Friedreich's ataxia, Roussy-Levy syndrome, Dejerine-Sottas syndrome, and spina bifida [4,5,7-11]. Traumatic cases may include severe burns, malunion of fractures, compartment syndrome, and crush injuries [7,12-14]. Congenital disorders, such as syphilis, lymphedema, arthrogyphosis, and clubfoot, have also been reported [4,6,7,13,15]. The cavus foot rarely presents before the age of 3 but may progress depending on the etiology [16]. It is important to perform a thorough neurological evaluation at the first sign of pathology to prevent a delay in diagnosis.

Evaluation and classification

A complete history is the basis of any patient encounter, but it is of the utmost importance when a patient has pes cavus. It is important to obtain a birth history and family history and to inquire about any developmental delays [17]. In the pediatric population a cavus foot should be considered a sign of a neuromuscular disorder until proven otherwise. Treatment of any underlying disease should take precedence over treatment of the foot deformity [18].

In adults, examination of the cavus foot may or may not yield any neurologic or muscular abnormalities. The presenting complaint is often pain or weakness in the arch, fatigue, ankle joint instability, heel pain, or pain under the metatarsal heads. As the deformity worsens, the amount of the foot that comes in contact with the ground decreases and the remaining weight-bearing areas are subjected to increased pressure. As a result, the patient often shows signs of callus plantar to the metatarsal heads [7]. Plantar callus can lead to ulceration in the neuropathic individual.

When ankle joint instability is the presenting complaint the amount of heel varus should be recognized (Fig. 1). Heel varus will increase as the cavus foot progresses, therefore leading to recurrent ankle sprains and instability. One must remember that with rearfoot varus the midtarsal joint is locked and subtalar joint pronation is limited [6]. A thorough gait examination may go a long way in aiding with the diagnosis. Furthermore, excessive wear on the lateral aspect of shoes may be noted. After gait analysis, a manual muscle examination should be performed.

Manual muscle testing aids in the identification of imbalance between strong and weak muscles. In neuromuscular disease, weakness of a muscle group results in overpowering by that muscle's antagonist. Agonist and antagonist muscles should be tested. Anterior muscles will oppose the triceps surae. The anterior tibialis muscle is the antagonist of the peroneus longus, whereas the posterior tibialis opposes the peroneus brevis muscle. In a study by Tynan [19], it was

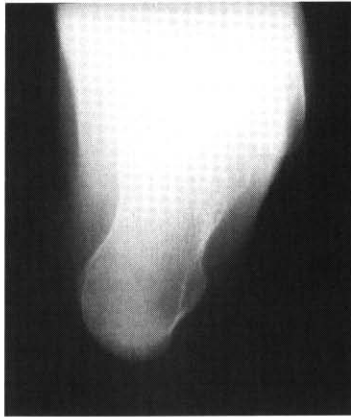

Fig. 1. Calcaneal axial radiographic view of rigid hindfoot varus.

noted that patients with a cavus deformity usually have a dominant peroneous longus compared with a weak anterior tibialis. Often, in Charcot-Marie-Tooth for example, the peroneous brevis and anterior tibialis muscles are weak. This leads to unopposed pull by the posterior tibialis and peroneous longus respectively. Hansen has coined the latter process "peroneal longus overpull" [12]. Progression of these imbalances leads to calcaneal varus, forefoot adduction, and plantarflexion of the first ray. The degree of muscle imbalance will become paramount if surgery is later performed [7,20].

Another aspect of the clinical examination for a patient with pes cavus is the block test. Coleman and Chestnut [21] popularized the test as a simple way to evaluate the flexibility of the hindfoot. The test is performed by placing the lateral border of the foot on an elevated block. The medial aspect of the foot is suspended off the block and as the patient attempts to bear weight the rearfoot is assessed. Surgical treatment of the rearfoot is unnecessary if it is flexible. If it is a rigid deformity, then surgical treatment may include the forefoot and rear-foot [17,21,22].

The next step in the evaluation of pes cavus is radiographic assessment. A weight-bearing lateral view is especially helpful (Fig. 2). Several radiographic angles may be obtained to help evaluate the apex of maximum deformity. The calcaneal inclination angle measures the plantar aspect of the calcaneus with the weight-bearing surface. Normal measurement is around 25 degrees, and anything over 30 degrees should be considered a moderate deformity. The long axes of the talus and first metatarsal create Meary's angle. A normal measurement is 0 to 5 degrees, but one study found an average of 18 degrees in patients with Charcot-Marie-Tooth [17,23,24]. Hibb's angle is formed by the axis of the first metatarsal with the body of the calcaneus. Barenfield [25] suggested a lesser-known calcaneometatarsal angle formed by the long axis of the first metatarsal with the axis of the calcaneus. Normal value is said to be less than 140 degrees with a decreased measurement in the cavus foot [25,26].

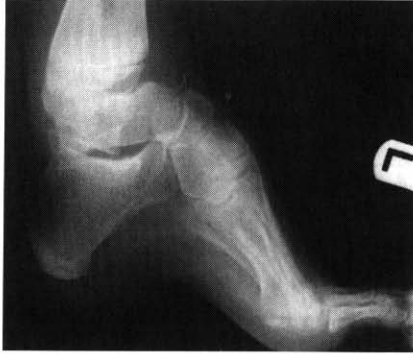

Fig. 2. Weight-bearing lateral radiographic view with severe increase in calcaneal inclination angle.

Pes cavus may be classified not only as flexible and rigid but also according to the findings of the radiographic evaluation. In anterior cavus the apex of the deformity is at either Lisfranc's or Chopart's joint. Meary's angle would be greater than 10 degrees and the calcaneal inclination would be less than 30 degrees. Posterior cavus has an apex of deformity proximal to Chopart's joint. Meary's angle is less than 10 degrees while calcaneal inclination is greater than 30 degrees. It is not unusual for both anterior and posterior deformities to be present. If this is the case, the patient is classified as having a combined cavus foot type. Further classification exists depending on the extent of the anterior cavus. For example, if the first metatarsal is plantarflexed alone in relation to the midtarsal and subtalar joints, this is classified as anterior local cavus. On the other hand, if all metatarsals are plantarflexed it is an anterior global deformity [27].

Finally, a complete evaluation may include a few other ancillary tests. Electromyography accompanied with nerve conduction velocity studies may be requisite based on the patient's neurological examination. In rare cases, muscle and nerve biopsy may be required for identification of various neurologic disorders [7]. Biopsies are usually performed only when clinical, radiographic, and electrodiagnostic studies fail to discern the underlying entity [6].

Associated conditions

Several associated conditions may be present in the cavus foot. Contracted digits are one of the most common accompanying deformities. The typical contracture of the toes seen in the cavus foot led early authors on the subject to describe the deformity as clawfoot [1]. Hammertoe-type deformities in pes cavus are often caused by extensor substitution. In extensor substitution the extensor digitorum longus muscle overpowers the lumbricales during swing phase and causes dorsiflexion and retrograde buckling at the metatarsal phalangeal joints. In

the cavus foot this may be precipitated by loss or weakness of the anterior tibialis muscle.

Because the weight-bearing surface of the foot is in essence decreased in the cavus foot, patients are prone to developing metatarsalgia and plantar heel pain. Heel pain may be due to plantar fasciitis or contracture, but often it is simply the result of contusion conditions from the increased force of weight bearing [12].

There are several other conditions or components of pes cavus that must be mentioned. For example, the plantarflexed first ray is an excessively plantarflexed first metatarsal relative to metatarsals 2 through 5. Forefoot valgus is described as an everted forefoot relative to the rearfoot when the subtalar joint is in neutral. Conversely, forefoot varus is described as an inverted forefoot relative to the rearfoot in subtalar joint neutral position. Next, rearfoot varus is an inverted position of the calcaneus compared with the weight-bearing surface while in subtalar joint neutral position [4]. Also, metatarsus adductus may be present concomitantly with pes cavus (Fig. 3) [28]. At our institution, a transverse plane midfoot osteotomy is used to correct any accompanying adductus when performing cavus reconstruction.

Surprisingly, equinus may be an associated condition of pes cavus. It is manifested as an overpowering of the posterior muscles, often with accompanied weakness of the anterior muscles, which leads to decreased ankle joint dorsiflexion. It may occur in patients with neuromuscular disorders, such as Charcot-Marie-Tooth, muscular dystrophy, and spina bifida. It is common to see spastic equinus with cerebral palsy. Pseudoequinus is not a true equinus but it is a

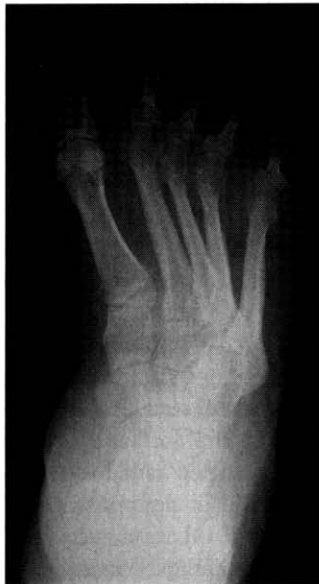

Fig. 3. Severe metatarsus adductus as an associated condition of cavus deformity.

condition that occurs when the ankle joint functions as if there is an equinus deformity. Pseudoequinus is common in rigid anterior pes cavus. The patient's foot dorsiflexes in an attempt to get the heel to the floor. This compensation may lead to an increased calcaneal inclination angle. The remaining inability of the ankle to dorsiflex during weight bearing is termed "pseudoequinus." Long-standing pseudoequinus in the cavus foot may sometimes result in spurring at the talar navicular joint. When a bony blockage leads to limitation of ankle dorsiflexion, osseous equinus occurs [4,29].

Conservative treatment

According to Mosca [18], there is little role for nonoperative treatment of the cavus foot because deformities are progressive in nature and severe by the time of presentation. An attempt should be made initially at conservative treatment. Patients with mild deformities will benefit most from conservative treatment. Operative treatment may be appropriate if there is an underlying medical condition. Nonsurgical treatment may be as simple as palliative care in the form of hyperkeratosis debridement. Further conservative care should consist of physical therapy, accommodative shoes, and orthoses.

Physical therapy may consist of daily stretching exercises for the Achilles tendon and plantar fascia. These stretches are not unlike those routinely prescribed for patients with plantar fasciitis. Stretching helps maintain suppleness in the arch of the foot and aids in treating an equinus deformity. Dwyer [16] advocated plantar fascia stretching in conjunction with a metatarsal bar for cavus deformities [17]. Aggressive physical therapy is especially important in neuromuscular diseases such as cerebral palsy. Treatment in cerebral palsy should begin at an early age and combine daily stretching with splinting and bracing. Muscle strengthening exercises will aid in gait stability of the cavus foot.

Accommodative shoes are another aspect of conservative treatment. Custom-made shoes are especially important in neuropathic patients to prevent ulcerations. Shoes can be accommodated to unload undue pressure at the heel and metatarsal heads. Materials such as PPT and Plastizote provide cushioning and limit shear forces [7].

It is important to provide the patient with some form of an orthotic device. Inserts and ankle-foot-orthoses may be used in conjunction with custom-made shoes. Patients with a rigid plantarflexed first ray and a flexible hindfoot may benefit from an orthotic with a medial forefoot post that helps eliminate hindfoot inversion [23]. A solid or articulated ankle-foot-orthotic can provide needed stability in a patient with significant deformity. It is extremely important that individuals are carefully fitted with these devices to prevent breakdown of the skin while providing the proper stability. When dispensing any type of orthotic, remember that periodic adjustments will most likely be necessary due to the progressive nature of most deformities.

Surgical intervention

Indications for surgical correction include pain, progressive deformity, and ankle instability. The goals of surgery are to balance muscle forces, correct deformities, and provide a mobile plantigrade foot [17,18]. It is important not only to determine the apex of the deformity but to address the entire deformity. No single procedure or algorithm can be used exclusively to correct pes cavus. Surgical correction consists of soft tissue and osseous procedures. Soft tissue releases and tendon transfers are useful for flexible deformities and as adjuncts to osseous procedures. In the actively growing pediatric patient, osseous procedures may not be acceptable, but remember that soft tissue procedures will not correct rigid deformities. The progressive nature of many neurologic conditions will make soft tissue correction temporary at best [27]. Because of the myriad of etiologies and associated deformities, a wide variety of surgical techniques are necessary to correct the symptomatic cavus foot.

Soft tissue procedures

Initial soft tissue procedures include plantar fascial release and Steindler stripping. Thomas [30] first reported using plantar fasciotomies for pes cavus. Later, the procedure was used alone for correction of cavus deformity caused by clubfoot and polio [31]. Today it is used primarily as an adjunct to osseous procedures. Steindler stripping is a release of the plantar fascia coupled with release of the plantar intrinsic musculature [32,33]. Typically, the abductor hallucis, abductor digiti quinti, and flexor digitorum brevis are stripped from the calcaneus. Modifications have been reported to avoid injury to the plantar neurovascular structures [7,34]. Regardless of the exact procedure, the calcaneal inclination angle should theoretically decrease with release of the windlass mechanism.

Tendon transfers

Tendon transfers are used to correct flexible deformities. A muscle should not be transferred unless its strength is at least grade 4 of 5, as transferred tendons will lose one grade in strength [35]. Transfers include the peroneus longus, posterior tibialis, and anterior tibialis. Peroneus longus transfer is indicated for a flexible plantarflexed first ray, and it is useful for any condition that causes a weak anterior tibialis muscle and dropfoot. Transfer of the peroneus longus not only eliminates first metatarsal plantarflexion but aids in dorsiflexion of the ankle [36]. Similarly, other augmentations of the peroneus longus may be useful in correcting a flexible plantarflexed first ray. These include lengthening as well as transfer or tenodesis to the peroneus brevis to combat excess plantarflexion.

Posterior tibialis tendon transfer can be risky because it is an out-of-phase transfer. Despite this, with proper physical therapy the procedure is useful for the treatment of dropfoot and a weak anterior tibialis muscle. The procedure reduces the deformity and also allows the patient to function better without bracing. If the individual acquires an equinus component then a gastrocnemius recession or Achille's lengthening may be necessary at the time of transfer [36].

In the inverted foot, if the anterior tibialis muscle remains strong, the tendon can be split and transferred laterally. This will aid in ankle dorsiflexion and decrease swing phase supination. Careful evaluation of anterior tibialis muscle strength should be performed before undertaking this procedure.

Another well-known soft tissue procedure is the Jones tenosuspension. The extensor hallucis longus tendon is transferred proximally from the hallux to the first metatarsal to correct plantarflexion. The procedure also consists of arthrodesis of the hallux interphalangeal joint. The extensor hallucis longus functions as an ankle dorsiflexor while metatarsal phalangeal joint extension is eliminated [37]. Similar surgical techniques, such as a modified Hibb's procedure, consist of transfer of the extensor digitorum longus to the lateral cuneiform, cuboid, or lesser metatarsals [38]. These transfers are indicated for flexible anterior cavus and correction of concomitant hammertoe deformities.

Osseous procedures

Soft tissue procedures are used for flexible deformities, and osseous correction is warranted for correction of rigid cavus foot deformities. Most osseous surgical procedures are used in conjunction with other procedures. A first metatarsal dorsiflexory wedge osteotomy is useful for treatment of a rigid plantarflexed first ray. Callus under the plantar aspect of the first metatarsal is a symptom of this fixed deformity. At our institution, a single 3.5-mm cortical screw is preferred for internal fixation. Another technique is to fixate the wedge with a three- or four-hole one-quarter or one-third tubular plate along with 2.7-mm or 3.5-mm cortical screws [39].

A Lapidus procedure may also be performed to allow for the appropriate amount of dorsiflexory correction. This surgical approach may be especially useful in the presence of metatarsus varus and marked neuromuscular disease [4,12]. McElvenny and Caldwell [40] initially recommended first metatarsal cuneiform joint arthrodesis to remedy anterior cavus by elevating and supinating the metatarsal. First metatarsal cuneiform arthrodesis may be fixated with 3.5-mm cortical or 4.0-mm cortical or cancellous screws with or without a plate. Again, cancellous bone may be used as a shear-strain relief bone graft across the joint to combat micromotion [41]. In some instances, anterior cavus may be corrected with multiple metatarsal osteotomies. A three-incisional approach should be employed over the base of the first metatarsal and between the bases of the second and third as well as the fourth and fifth metatarsals respectively.

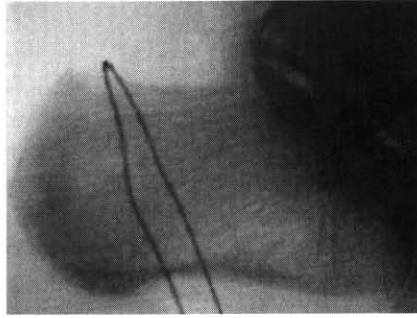


Fig. 4. Placement of percutaneous giggly saw just before through-and-through calcaneal osteotomy.

Jahss [42] described a truncated wedge arthrodesis of the tarsometatarsal joint for fixed anterior cavus. The procedure is essentially a Lis Franc's joint arthrodesis. The base of the wedge is wider at the dorsal aspect compared with plantar, and the forefoot is elevated out of its plantarflexed attitude. The procedure should not be used to correct subtalar or rearfoot pathology. As with any cavus reconstruction, determining the apex of the deformity is mandatory. Overzealous resection of the wedge or excision distal to the apex of the deformity can lead to a postoperative rocker-bottom foot [4].

A calcaneal osteotomy is indicated in the presence of rigid hindfoot varus. The Coleman block test should be performed to be certain that the varus position of the calcaneus is not reducible. We prefer a percutaneous displacement osteotomy of the calcaneus and believe that fixation is best accomplished with a pair of parallel percutaneous 7.3-mm cannulated screws driven from posterior-inferior to anterior-superior across the osteotomy site. An alternative to the percutaneous osteotomy is the Dwyer lateral closing wedge osteotomy. These can be performed with the standard open technique or in a percutaneous fashion (Fig. 4); the former method can be used with the aid of a giggly saw (Fig. 5) [43]. Dwyer believed that a plantar fascial release was a supplemental requirement

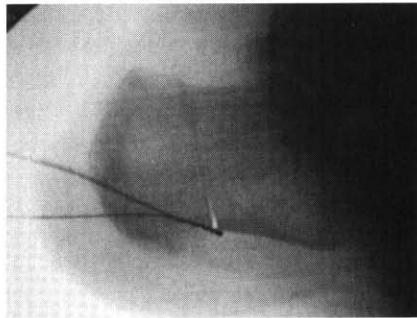


Fig. 5. Giggly saw technique immediately after performing calcaneal osteotomy. Two 7.3-mm cannulated screws were then driven from posterior to anterior across the osteotomy site.

[44]. Similarly, the authors perform a plantar fasciotomy or Steindler stripping as an adjunctive procedure. A preponderance of ankle equinus as a result of ankle plantarflexors overpowering the anterior muscles is common. A tendo-Achilles lengthening or gastrocnemius recession is performed under these circumstances.

Triple arthrodesis is a common procedure for correction of severe pes cavus with associated arthrosis. It is also useful as a salvage procedure in skeletally mature adolescents with rigid pes cavus [17,35,45]. With proper wedge resection, triple arthrodesis is a powerful technique that can correct all three planes of deformity.

Midfoot osteotomies

Midfoot osteotomies are useful in reducing rigid anterior cavus deformities. Several variations have been used over the years to enhance correction. Regardless of the level, plane, or technique of the midfoot osteotomy, the aforementioned adjunctive procedures aid in the complete correction of the deformity.

Cole procedure

Cole [1] described a closing wedge osteotomy with removal of a dorsally based wedge. The wedge is removed from a distal cut through the cuboid and cuneiforms coupled with a proximal cut through the cuboid and navicular. This elevates the forefoot out of equinus. Although Cole is credited with popularizing the procedure, it was first described by Saunders 5 years earlier [15]. The Cole procedure is indicated for rigid anterior pes cavus when the apex of the deformity

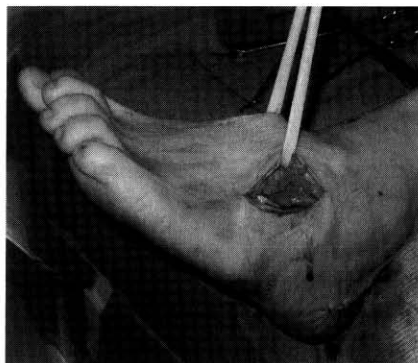

Fig. 6. Cole procedure soft tissue dissection of lateral incision.

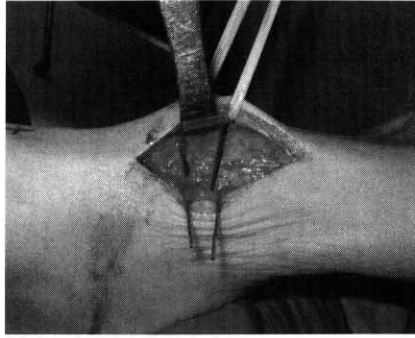


Fig. 7. An approximately 1-cm dorsally based wedge. The medial aspect of the wedge can be made wider to address associated metatarsus adductus.

is located at the midfoot. It is contraindicated when the apex of the deformity is any place other than the midfoot [1,46]. Also, the procedure is not indicated for the skeletally immature foot, as this can lead to shortening. It is important that the talonavicular and calcaneal-cuboid joints are spared during this procedure. In addition, an osteotomy with a wider medial wedge has been proposed as a modification for multiplanar correction or more often a wider lateral wedge is used to address adduction [47].

The Cole midfoot osteotomy has been employed with one-, two-, and three-incision approaches [46]. We prefer a two-incision approach (Fig. 6). A medial incision is extended from the first metatarsal cuneiform joint to the navicular. A lateral incision is placed over the cuboid. Care is taken to use blunt dissection to avoid the dorsalis pedis artery and the anterior tibialis tendon with the medial incision and the sural nerve with the lateral. A power sagittal saw or a long oscillating saw is then used for the osteotomy. The dorsal base should be approximately 1 cm wide (Fig. 7). The apex of the wedge should meet at the plantar aspect of the navicular and cuboid (Fig. 8). At this time, associated

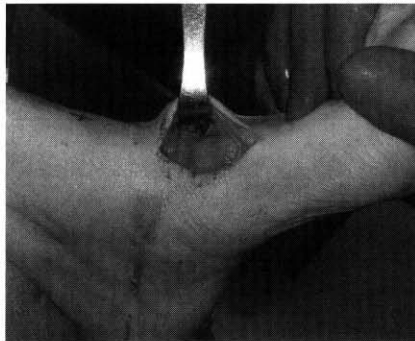


Fig. 8. Reduction of midfoot osteotomy after wedge removal.

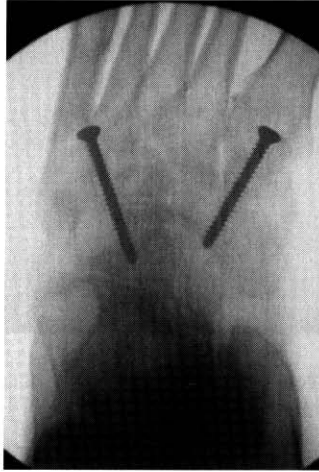

Fig. 9. AP radiograph after reduction and fixation of midfoot osteotomy.

metatarsus adductus can be combated by making the lateral aspect of the wedge wider. A Steindler stripping is necessary to aid in dorsiflexion of the osteotomy site. Fixation may consist of any combination of Steinman pins, staples, and screws. Care must be taken when using screws that the surrounding joint spaces are not violated. Some surgeons prefer to use screws in combination with a quarter tubular plate [39]. We prefer 3.5-mm cortical screws for fixation (Figs. 9 and 10). Fixation is stable with postoperative weight bearing because of the benefit of ground reactive forces across the osteotomy site. Weight bearing to tolerance with a cast and crutches is usually allowable after only a few weeks. At about 4 weeks the cast may be replaced by a Cam Walker until bone healing is complete.

A recent study by Wulker and Hurchler [48] reported satisfaction in eight of 11 patients who required a dorsal closing wedge osteotomy for pes cavus. Of the

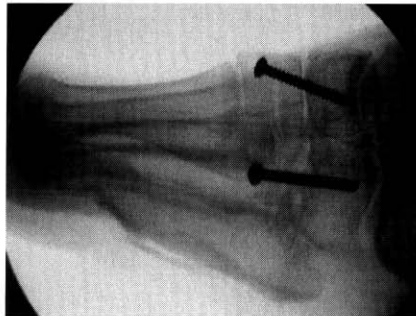

Fig. 10. Cole midfoot osteotomy lateral radiographic view after screw fixation.

patients not satisfied with the outcome of surgery, two went on to a nonunion and the third required subsequent Achilles's tendon lengthening to correct an underlying equinus deformity [48]. Furthermore, a gastrocnemius recession or Achilles's lengthening is often necessary to correct the equinus deformity before osseous reconstruction of the midfoot.

Japas midfoot osteotomy

Japas [2] described a through-and-through V-shaped osteotomy that was designed to circumvent shortcomings of the Cole procedure, such as shortening of the foot. The technique is indicated for anterior pes cavus and serves to elevate the forefoot into a more rectus position. It is not advised in the immature foot. The transverse plane V-shaped osteotomy is performed with the apex proximal in the navicular and the arms extending distally through the cuboid and the first cuneiform respectively [2]. A single dorsal longitudinal incision is most often used. Steinman pins are the most common form of fixation.

An advantage of this procedure is that a wedge need not be removed, and therefore the foot does not shorten. However, the disadvantages outweigh this advantage. The Japas procedure can often lead to arthrosis and delayed union [4]. Also, the patient may be left with an uncomfortable hump that is created on the dorsal aspect of the foot. It is our belief that the Cole procedure is easier, more reliable, and has fewer complications.

Midtarsal dome osteotomy

Wilcox and Weiner [26] advocated an alternative approach for correction of rigid anterior cavus. The results of the subsequent study demonstrated a 94% satisfaction rate in patients older than 8 years of age, but only 42% satisfactory results were obtained in patients younger than 8 [26]. The procedure is indicated when the apex of the deformity lies in the midfoot. It does not aid in correction of hindfoot varus or metatarsus adductus.

Surgical technique consists of a dorsal transverse incision over the midfoot region. A curved osteotome is used to fashion the osteotomy. The 1-cm-wide dome osteotomy can be performed through the cuneiforms, cuboid, and base of the fifth metatarsal. The dome shape allows for three-dimensional correction of the deformity and provides optimal bony contact for healing. Steinman pins provide adequate fixation. As with other midfoot osteotomies, a plantar fascial release is often used as an adjunct [26]. Although the procedure is an acceptable alternative to other midfoot osteotomies, it may cause shortening of the foot, and the shape of the osteotomy does not lend itself easily to making bone cuts.

Ilizarov

The Ilizarov method of external fixation is useful for correction of complex foot deformities because of its three-dimensional nature. It may be used with an accompanying midfoot osteotomy for correction of pes cavus. The osteotomy can be safely positioned across the cuboid and navicular or the cuboid and cuneiforms with fluoroscopy to form a sufficient surface for bone regeneration [37,49,50].

Advantages of the Ilizarov method include that it is minimally invasive, thus the chance of soft tissue and neurovascular damage is decreased [49]. This method allows for dynamic three-dimensional correction and can simultaneously correct other associated lower extremity deformities [49,51]. The major advantage over internal fixation is that it can be adjusted postoperatively to better obtain the desired correction and position of the foot [49]. Furthermore, its inherent stability allows for early weight bearing and allows for a dynamic repositioning of soft tissue structures to correct a flexible component of the deformity.

Surgical technique may be performed through a single dorsal incision or through the combination of one medial and one lateral incision. Care must be taken to protect the plantar and dorsal neurovascular structures from damage. Our incision placement and dissection is similar to that described by Hamilton and Ford [52]. The medial incision runs from the base of the first metatarsal and proximally to the navicular. The lateral incision is centered over the cuboid. A dorsally based wedge of bone is removed from the midfoot in a similar fashion to the Cole procedure. A V-shaped osteotomy is an acceptable alternative. Surgeons in modern-day Russia often use this V-shaped osteotomy through cancellous bone at the level of the talar neck and calcaneus to promote osseous regeneration. Placement of an Ilizarov frame obviates the need for internal fixation in most cases. Construction of the frame may vary depending on associated conditions. A stable apparatus usually consists of a base frame with at least two proximal rings around the leg [51,53]. The heel frame should consist of crossed smooth wires, half pin in the calcaneus to act as a motor to allow circumferential rotation of the hind foot. Hinges must be placed at the level of the malleoli to allow for the proper rotation. The frame is then completed with a forefoot component at the level of the metatarsals. The patient may begin weight bearing to tolerance as soon as possible. Early weight bearing and dynamic correction make the Ilizarov method of external fixation a viable option for cavus foot deformities.

Miscellaneous midfoot osteotomies

A wide variety of lesser-known midfoot osteotomies have been advocated for the cavus foot. Giannini and associates [54] reviewed one such technique in 39 patients who were treated for idiopathic pes cavus. Treatment consisted of a cuboid osteotomy that was performed in conjunction with a naviculocuneiform

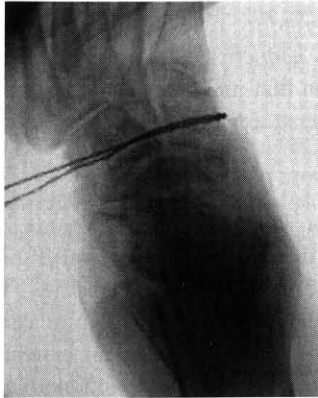


Fig. 11. Placement of giggly saw just before midfoot osteotomy. Care is taken to remain in close contact with bone so as not to injure neurovasculature.

fusion and a plantar fasciotomy. The study reported good or excellent results in 72% of the patients, with success being dependant on patient satisfaction and proper biomechanics of the foot and ankle during postoperative gait analysis [54].

Our institution sometimes performs percutaneous midfoot osteotomies. A giggly saw is used in such cases and provides for an efficient and minimally invasive alternative to a standard osteotomy. A stab incision is placed at the dorsal medial aspect of the midfoot, and special care is taken to perform blunt subperiosteal dissection. The saw is placed through the incision, and care is taken to remain in close contact with the bone so as to remain plantar to all dorsal neurovasculature (Fig. 11). The saw may then exit through a stab incision at the dorsal lateral aspect of the midfoot. Two other stab incisions are created at the plantar medial and plantar lateral aspects, and fluroscopy is then used to ensure proper placement of the saw during the osteotomy (Fig. 12).

Other procedures, such as isolated cuneiform and cuboid osteotomies, can be used as an adjunct. Alone, these procedures have little effect on a cavus

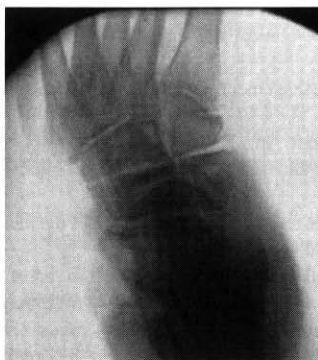

Fig. 12. Midfoot after percutaneous giggly saw osteotomy.

deformity. Cuneiform osteotomy may be useful in aiding in the correction of accompanying metatarsus adductus, whereas a cuboid osteotomy is helpful for residual forefoot abduction that may present with a cavus deformity [55].

Summary

Surgical correction of the cavus foot is a challenging task. It is important to determine the apex of the deformity and to address the entire deformity. It is important to remember that no single procedure can be used exclusively to correct pes cavus. Midfoot osteotomies are an essential component of surgical correction. They can be combined with adjunctive procedures to form an appropriate strategy for the treatment of severe pes cavus.

References

- [1] Cole WH. The treatment of claw foot. *J Bone Joint Surg* 1940;22:895–908.
- [2] Japas LM. Surgical treatment of pes cavus by tarsal v-osteotomy. *J Bone Joint Surg [Am]* 1968;50:927–44.
- [3] Berg EE. Chinese foot binding. *Orthop Nurs* 1995;14:66–8.
- [4] Smith TF, Green DR. Pes cavus. In: Banks AS, Downey MS, Martin DE, Miller SJ, editors. McGlamry's comprehensive textbook of foot and ankle surgery. 3rd edition. Philadelphia: Lippincott Williams and Wilkins; 2001. p. 761–98.
- [5] Brewerton DA, Sandifer PH, Sweetman DR. Idiopathic pes cavus: an investigation into its etiology. *BMJ* 1963;1:659–61.
- [6] Hsu JD, Mann DC, Imbus CE. Pes cavus. In: Jahss MH, editor. Disorders of the foot and ankle. Philadelphia: WB Saunders; 1991. p. 872–91.
- [7] Wapner KL. Pes cavus. In: Myerson MS, editor. Foot and ankle disorders. Philadelphia: WB Saunders; 2000. p. 919–41.
- [8] Colon MJ, Whitton KE, Schwartz N. Treatment of pes cavus in a patient with Charcot-Marie-Tooth disease. *J Foot Surg* 1980;19:41–4.
- [9] Fenton CF, McGlamry ED, Perrone M. Severe pes cavus deformity secondary to Charcot-Marie-Tooth disease: a case report. *J Am Podiatry Assoc* 1982;72:171–5.
- [10] Tyrer J. Friedreich's ataxia. In: Vinken PJ, Bruyn GW, DeJong JM, editors. System disorders and atrophies: handbook of clinical neurology, vol. 21. Amsterdam: Elsevier Science; 1975. p. 319–64.
- [11] Makin M. The surgical management of Friedreich's ataxia. *J Bone Joint Surg [Am]* 1953; 35:425–36.
- [12] Hansen ST. Cavovarus foot. In: Hurley R, Seigafuse S, Marino D, editors. Functional reconstruction of the foot and ankle. Philadelphia: Lippincott Williams and Wilkins; 2000. p. 209–13.
- [13] Ibriham K. Pes cavus. In: Evarts CM, editor. Surgery of the musculoskeletal system. New York: Churchill Livingstone; 1990. p. 4015–34.
- [14] Home G. Pes cavovarus following ankle fracture: a case report. *Clin Orthop* 1984;184:249–50.
- [15] Saunders JT. The etiology and treatment of clubfoot. *Arch Surg* 1935;30:179–98.
- [16] Dwyer FC. The present status of the problem of pes cavus. *Clin Orthop* 1975;106:254–75.
- [17] Schwend RM, Drennan JC. Cavus foot deformity in children. *J Am Acad Orthop Surg* 2003; 11:201–11.
- [18] Mosca VS. The cavus foot. *J Pediatr Orthop* 2001;21:423–4.

- [19] Tynan MC, Klenerman L, Helliweller TR. Investigation of muscle imbalance in the leg and symptomatic forefoot pes cavus in a multidisciplinary study. *Foot Ankle* 1992;13:489–501.
- [20] Olney B. Treatment of the cavus foot Deformity in the pediatric patient with Charcot-Marie-Tooth. *Foot Ankle Clin* 2000;5(2):305–15.
- [21] Coleman SS, Chestnut WJ. A simple test for hindfoot flexibility in the cavovarus foot. *Clin Orthop* 1977;123:60.
- [22] Paulos L, Coleman SS, Samilson KM. Pes cavovarus: review of a surgical approach using selective soft tissue procedures. *J Bone Joint Surg [Am]* 1980;62:942–53.
- [23] Alexander IJ, Johnson KA. Assessment and management of pes cavus and Charcot-Marie-Tooth disease. *Clin Orthop* 1989;246:273–81.
- [24] Jahss MH. Evaluation of the cavus foot for orthopedic treatment. *Clin Orthop* 1983;181:52–63.
- [25] Barenfield PA, Weseley MS, Shea JM. The congenital cavus foot. *Clin Orthop* 1974;79:119–26.
- [26] Wilcox PG, Weiner DS. The Akron midtarsal dome osteotomy in the treatment of rigid pes cavus. *J Pediatr Orthop* 1985;5(3):333–8.
- [27] Jay RM. Cavus deformity. In: Jay RM, Donley S, editors. *Pediatric foot and ankle surgery*. Philadelphia: WB Saunders; 1999. p. 211–9.
- [28] Steinwender W, Linhart WE. High arched forefoot, pes cavus metatarsus congenitus: a case report. *Z Orthop Ihre Grenzgeb* 1991;129:240–2.
- [29] Whitney AK, Green DR. Pseudoequinus. *J Am Podiatry Assoc* 1982;72:365–71.
- [30] Thomas W. On the treatment of talipes cavus. *Birmingham Med Rev* 1917;34:1–5.
- [31] Sherman FC, Westin GW. Plantar release in the correction of deformities of the foot in childhood. *J Bone Joint Surg [Am]* 1981;63:1382–9.
- [32] Steindler A. Operative treatment of pes cavus. *Surg Gynecol Obstet* 1917;24:612–5.
- [33] Steindler A. Stripping of the os calcis. *Am J Orthop Surg* 1920;2:8–12.
- [34] Mann RA. Pes cavus. In: Mann RA, Coughlin MJ, editors. *Surgery of the foot and ankle*. St. Louis (MO): Mosby; 1993. p. 785–801.
- [35] Samilson RL, Dillin W. Cavus, cavovarus, and calcaneovarus: an update. *Clin Orthop* 1983;177:125–32.
- [36] Hansen ST. Tendon transfers and muscle balancing techniques. In: Hurley R, Seigafuse S, Marino D, editors. *Functional reconstruction of the foot and ankle*. Philadelphia: Lippincott Williams and Wilkins; 2000. p. 433–50.
- [37] Holmes JR, Hansen ST. Foot and ankle manifestations of Charcot-Marie-Tooth disease. *Foot Ankle* 1993;14:476–86.
- [38] McGlamry ED, Butlin WE, Ruch JA. Treatment of forefoot equinus by tendon transpositioning. *J Am Podiatry Assoc* 1975;65:872–88.
- [39] Hansen ST. First metatarsal osteotomy for correction of fixed first metatarsal cavus deformity. In: Hurley R, Seigafuse S, Marino D, editors. *Functional reconstruction of the foot and ankle*. Philadelphia: Lippincott Williams and Wilkins; 2000. p. 391–3.
- [40] McElvenny RT, Caldwell GD. A new operation for correction of cavus foot: fusion of first metatarsocuneiform navicular joints. *Clin Orthop* 1958;11:85–92.
- [41] Perren SM. The biomechanics and biology of internal fixation using plates and nails. *Orthopedics* 1989;12:21–34.
- [42] Jahss MH. Tarsometatarsal truncated-wedge arthrodesis for pes cavus and equinovarus deformity of the fore part of the foot. *J Bone Joint Surg [Am]* 1980;62:713–22.
- [43] Dull JM, DiDomenico LA. Percutaneous displacement calcaneal osteotomy. *J Foot Ankle Surg* 2004;43(5):336–7.
- [44] Dwyer FC. Osteotomy of the calcaneum for pes cavus. *J Bone Joint Surg [Br]* 1959;41:80–6.
- [45] Sullivan RJ, Aronow MS. Different faces of the triple arthrodesis. *Foot Ankle Clin* 2002;7(1):95–106.
- [46] Harley BD. Cole midfoot osteotomy. In: *Pediatric foot and ankle surgery*. Philadelphia: WB Saunders; 1999. p. 220–4.
- [47] Alvik I. Operative treatment of pes cavus. *Acta Orthop Scand* 1954;23:137–43.
- [48] Wolker N, Hurchler C. Cavus foot correction in adults by dorsal closing wedge osteotomy. *Foot Ankle Int* 2002;23(4):344–7.

- [49] Paley D. The correction of complex foot deformities using Ilizarov's distraction osteotomies. *Clin Orthop* 1993;293:97–111.
- [50] Bibbo C, Anderson RB, Davis WH. Complications of midfoot and hindfoot arthrodesis. *Clin Orthop* 2001;391:45–58.
- [51] Ilizarov GA, Shevtsov VI, Shestakov VA, Kuzmin NV. The treatment of foot deformities in adults by the Ilizarov transosseous osteosynthesis. *Methodological Recommendation Book*. Kurgon, Russia: Kurgon Internal Publication; 1987.
- [52] Hamilton GA, Ford LA. External fixation of the foot and ankle elective indications and techniques for external fixation in the midfoot. *Clin Podiatr Med Surg* 2003;20:45–63.
- [53] Kocaoglu M, Eralp L, Atalar AC. Correction of complex foot deformities using Ilizarov external fixator. *J Foot Ankle Surg* 2002;41(1):30–9.
- [54] Giannini S, Ceccarelli F, Benedetti MG, et al. Surgical treatment of adult idiopathic cavus foot with plantar fasciotomy, naviculocuneiform arthrodesis, and cuboid osteotomy: a review of 39 cases. *J Bone Joint Surg [Am]* 2002;84(2):62–9.
- [55] Hall RL. The use of osteotomy to correct foot and ankle deformities. In: Myerson MS, editor. *Foot and ankle disorders*. Philadelphia: WB Saunders; 2000. p. 1009–10.