

Revisiting the Tailor's Bunion and Adductovarus Deformity of the Fifth Digit

Lawrence DiDomenico, DPM^{a,b,*}, Erigena Baze, DPM^c,
Nikolay Gatalyak, DPM^d

KEYWORDS

• Tailor's bunion • Adductovarus • Deformity • Fifth digit

KEY POINTS

- Correction of the fifth digit deformity can be rewarding as well as challenging for a foot and ankle surgeon.
- Immense care should be taken when performing any digital procedure, especially of the fifth digits, to avoid and minimize complication rates and mainly to prevent neurovascular damage.

TAILOR'S BUNION

Introduction

Bunionette is a term used to characterize a lateral prominence of the fifth metatarsal head. The term tailor's bunion is also used to refer to this deformity and it is derived from the cross-legged position of a tailor, which places abnormal pressure on the lateral aspect of the fifth metatarsal head.¹⁻⁴ Like the bunion, a bunionette has a high association with constrictive shoes.^{3,5} The bunionette deformity usually consists of both an abnormal fifth metatarsal as well as overlying soft tissues. The deformities involving the fifth metatarsal and fifth metatarsophalangeal (MTP) joint are characterized by a symptomatic prominence of the fifth metatarsal, which can be accompanied by rotational deformities of the fifth digit. Symptoms can involve the dorsal, lateral, and plantar aspects of the fifth metatarsal head, but most commonly, increased pressure over the lateral condyle of the fifth metatarsal head can lead to chronic irritation of the overlying bursa.¹ Although the incidence and prevalence of tailor's bunionette deformity in the general population is not known, several retrospective studies indicate that

^a Ankle and Foot Care Centers/Kent State University College of Podiatric Medicine, 6000 Rockside Woods Boulevard Independence, OH 44131, USA; ^b St. Elizabeth Medical Center, 8175 Market Street, Youngstown, OH 44512, USA; ^c Heritage Valley Hospital Beaver, Beaver, PA 15108, USA; ^d Private Practice Ankle and Foot Care Centers, 750 E Park Avenue, Columbiana, OH 44408, USA

* Corresponding author.

E-mail address: ld5353@aol.com

the condition is between 3 and 10 times more common in women than men and has a peak incidence during the fourth and fifth decades of life.⁶ Conservative treatments such as changes in shoe gear, orthoses, various forms of pressure offloading pads, antiinflammatories, and corticosteroid injections are used in order to lessen the pain associated with a painful tailor's bunionette deformity. However, such modalities have not been shown to provide any long-term relief and merely treat the symptoms associated with the condition and not the deformity itself (**Fig. 1**).⁶⁻⁸

Cause

Haskell⁹ stated that a bunionette could be considered analogous to the medial eminence of the first metatarsal in hallux valgus. However, the cause and anatomic variations that are present with a bunionette seem to be more complex than those originally described by Kelikian and Davies. Several anatomic factors have been attributed to the development or presence of a bunionette deformity.¹⁰ The bunionette is often seen in splayfoot combined with hallux valgus, or the head of the fifth metatarsal may be congenitally or traumatically enlarged.¹¹ Also, the shaft may be angulated laterally, making the fifth metatarsal head more prominent.^{2,10} Consequently, constricting shoes are the main source of discomfort. With continuous pressure over the prominent fifth metatarsal, a bursa can develop as a result of chronic irritation to the area. Over time, this bursa can develop into an ulceration. In patients with diabetes, advanced Charcot-Marie-Tooth disease, or certain types of spinal dysraphism with poor sensibility, this complication can result in loss of the entire fifth ray or even the foot.²

According to Bertrand and colleagues,¹ the cause of bunionette deformities can be divided into 2 broad categories: anatomic and biomechanical.

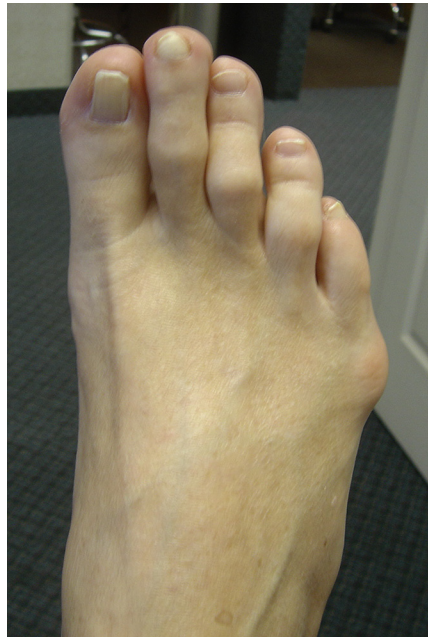

Fig. 1. A patient with a tailor's bunion and a chronic symptomatic irritation of the overlying bursa.

Anatomic causes could include the following:

- Tight footwear causing pressure over the lateral fifth metatarsal
- Abnormal foot position (lateral aspect of the foot resting on the ground)
- Prominent lateral fifth metatarsal head
- Hypertrophy of soft tissues overlying lateral aspect of the fifth metatarsal head
- Dumbbell-shaped fifth metatarsal
- Supernumerary ossicles attached to the lateral fourth metatarsal, pushing the fifth metatarsal laterally
- Increased fourth to fifth intermetatarsal (4–5 IM) angle (splaying)
- Incomplete insertion or development of the transverse metatarsal ligament.

Biomechanical causes could include the following:

- Lateral bending/deviation of the fifth metatarsal
- Congenital plantar or dorsiflexed fifth ray deformities
- Excessive pronation caused by hypermobility of the fifth metatarsal
- Subluxatory pronation of the fifth metatarsal (associated with pronation of subtalar and midtarsal joints)
- Pes planus (hindfoot eversion leads to a more laterally pronounced fifth metatarsal) (**Fig. 2**).

Evaluation

Clinical presentation

The major subjective complaints of a patient presenting with tailor's bunion are pain and irritation caused by friction between the underlying bony abnormality and restricting footwear. Patients complain of swelling, painful ambulation aggravated by shoe gear, and callus formation over the deformity (**Fig. 3**).^{12,13}

Classification

Various anatomic variations of the fifth metatarsal have been described in the literature and possible treatment options are based on these variations (see **Fig. 1A–C**). Three

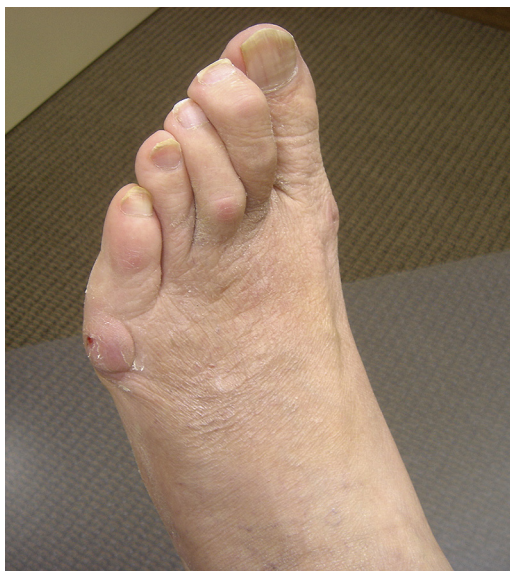

Fig. 2. A deformed fifth metatarsal associated with a painful bursitis.



Fig. 3. Constricting shoes, particularly in females, can be a source or a contributing factor in the discomfort of a tailor's bunion.

types of bunionette deformities have been described by Coughlin.³ The classification is based on weight-bearing dorsoplantar radiographs. In Coughlin's series of symptomatic bunionette deformities, a type I deformity was noted in 27% of cases, a type II deformity in 23% of cases, and type III in 50% of cases.^{1,9}

Type I is an enlargement of the lateral surface of the fifth metatarsal. Type I could be secondary to an exostosis; a prominent lateral condyle; or a round, or dumbbell-shaped, metatarsal head. It has been observed that with excessive pronation of the foot, the lateral plantar tubercle of the fifth metatarsal head rotates laterally to create the radiographic impression of an enlarged fifth metatarsal head.

Surgical procedure: a distal osteotomy is the suggested surgical treatment of this deformity (**Fig. 4**).

Type II is secondary to abnormal lateral bowing of the distal fifth metatarsal with a normal 4–5 IM angle. There is not usually associated hypertrophy of the fifth metatarsal head. The bowing of the fifth metatarsal is also called the lateral deviation angle. This angle is formed by 1 line drawn from the center of the fifth metatarsal head to its medial base and a second line made along the medial cortex of the fifth metatarsal. The average lateral deviation angle is normally 2.6° (range, 0°–7°). Symptomatic patients with bunionette deformities have an average value of 8.05° (range, 0°–16°).

Surgical procedure: a diaphyseal or distal osteotomy is the suggested surgical treatment of this deformity (**Fig. 5**).

Type III, the most common in Coughlin's series, is characterized by an increased 4–5 IM angle, with divergence of the fourth and fifth metatarsals.

The average 4–5 IM angle is 6.2° (range 3°–11°). In symptomatic patients with bunionette, the average IM angle is 9.6° (range, 5°–14°).^{14,15}

Surgical procedure: a diaphyseal or proximal osteotomy is the suggested surgical treatment of this deformity (**Fig. 6**).

Type IV, not described by Coughlin, is not common and consists of a combination of deformities, including 2 or more of the types listed earlier. This type is most commonly seen in the feet of patients with rheumatoid arthritis.¹

Although anatomic classification schemes and radiographic criteria are helpful in evaluating and treating bunionette deformities, patients may have increased angles

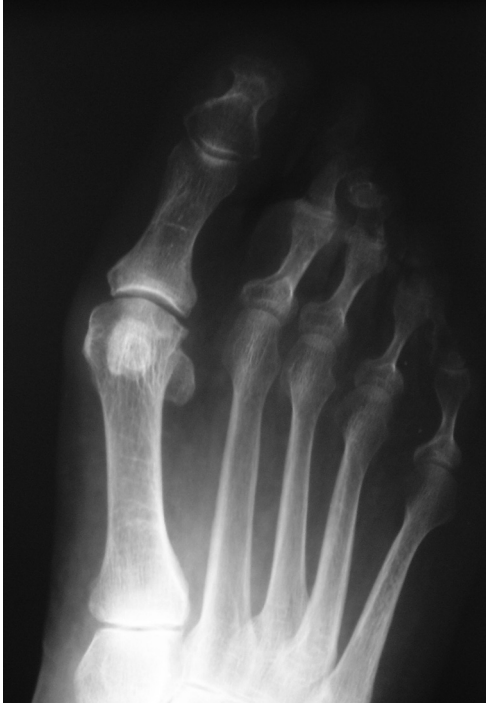

Fig. 4. A patient with a symptomatic enlarged lateral surface of the fifth metatarsal (type I).

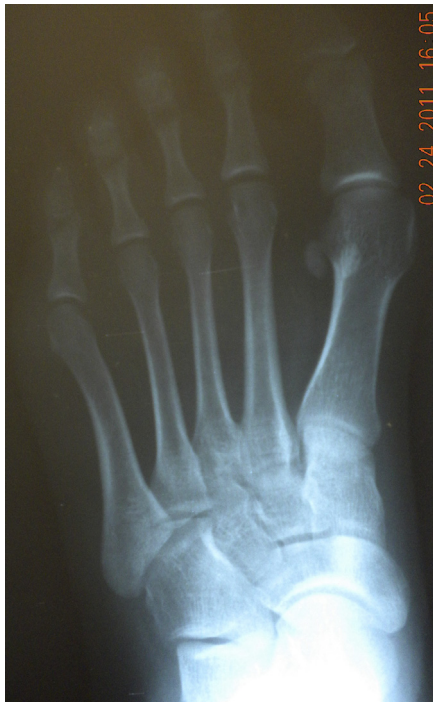

Fig. 5. An anteroposterior radiograph showing an abnormal lateral bowing of the distal fifth metatarsal with a normal 4-5 IM angle (type II).

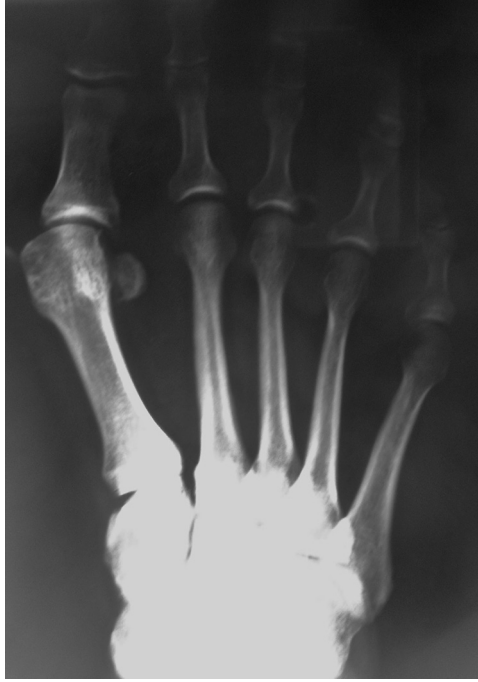

Fig. 6. An anteroposterior radiograph showing an increased IM angle with divergence of the fourth and fifth metatarsal heads.

and no symptoms, or patients may have more than 1 anatomic variation, complicating decision making. In addition, with pronation of the foot, the 4–5 IM angle was found to increase by 3° , and the fifth metatarsal head appears to increase in size, suggesting that radiographic technique may influence significantly preoperative and postoperative assessment.¹⁰

Regardless of the underlying anatomy, the common symptom that all patients with a bunionette deformity note is increased pressure over the fifth metatarsal head caused by constricting footwear. This symptom seems more exaggerated in the female population because of choices in fashionable shoe gear. Swelling of the soft tissues overlying the lateral aspect of the fifth metatarsal head can lead to pain. Three main painful areas that have been described in relation to the head of fifth metatarsal are laterally, dorsolaterally, and plantarly. Patients with a bunionette deformity often present with erythema and edema over a deformity on the lateral aspect of the foot. In immunocompromised patients, ulceration can occur, which can lead to superinfection. Over time, as continuous pressure is applied over the lateral aspect of the fifth metatarsal, a secondary hyperkeratotic lesion can develop over the lateral or plantar aspects of the fifth toe. This hyperkeratosis can occasionally cause the fifth toe to deviate medially at the MTP joint, whereas the metatarsal deviates laterally (**Figs. 7–9**).¹

Radiographic evaluation

Taylor's bunion deformity can be evaluated with plain foot weight-bearing radiographs. Anteroposterior (AP) and lateral radiographs are the standard views used to evaluate the deformity. Occasionally, a medial oblique (MO) view is performed to assess lateral flare, metatarsal head, lateral tubercle, and lateral soft tissues. The most common

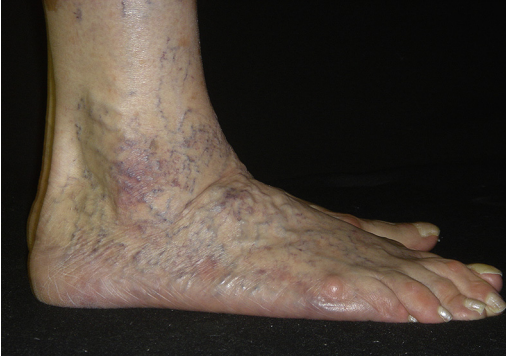

Fig. 7. A clinical view of a patient with dorsal lateral tailor's bunion pain.

radiographic angles used to evaluate tailor's bunion deformity are the 4–5 IM angle and lateral deviation angle.

The 4–5 IM angle measures the divergence of the respective metatarsal and can be achieved by the traditional method, bisecting the shafts of the fourth and fifth metatarsals. An alternative measurement to evaluate the divergence is using a line drawn along the medial and proximal border of the fifth metatarsal and bisection of the fourth metatarsal. According to Fallat and Buckholz,¹⁴ the average IM angle using the traditional method is 6.2° , with a range of 3° to 11° , although in their study, the average

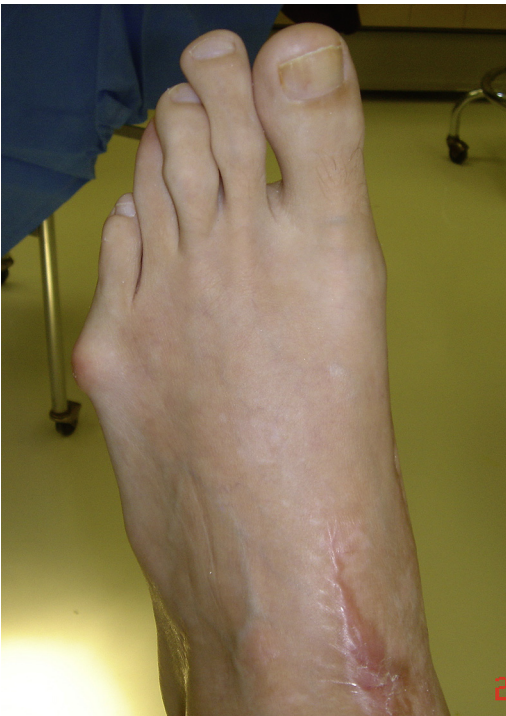

Fig. 8. A clinical view of a patient with lateral tailor's bunion pain.

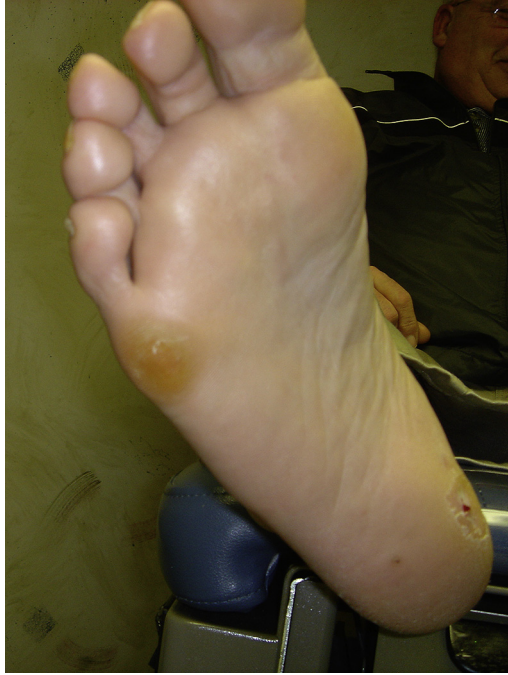

Fig. 9. A clinical view of a patient with plantar fifth metatarsal callus, causing pain.

angle in a symptomatic tailor's bunion deformity was 9.6° and may be increased an average of 3° in patients with pes planus deformity.

As the IM angle increases, more pressure is shown on the lateral metatarsal head, and the same can be observed with lateral deviation angle. The lateral deviation angle is a measurement of a line bisecting the metatarsal head and neck and a line drawn along the medial and proximal border of the metatarsal cortex. Fallat and Buckholz found the average angle in a normal foot to be 2.64° and 8.05° in patients with tailor's bunion deformity.

Physical examination

Emphasis is placed on evaluation of the foot and ankle for presence of adventitial bursa formations, keratotic lesions, and ulcerations. In addition, according to Roukis and colleagues,⁶ a detailed evaluation of the fifth metatarsal cuboid joint and fifth metatarsal phalangeal joint range of motion, global forefoot posture, and palpation of the periarticular structures to determine areas of maximum signs and symptoms and exostosis formation should be performed.

The clinical examination should include a thorough assessment of the patient's past and present medical history, with special emphasis placed on the chronicity of the symptoms, effect of the condition on their activities of daily living and employment responsibilities, and progression of the deformity.

However, weight-bearing radiographs are essential, and when combined with the clinical examination, allow complete evaluation in all but the most severe or unusual abnormalities involving the fifth metatarsal and fifth metatarsal phalangeal joint. Weight-bearing AP and lateral radiographs in the angle and base of gait should be made of both feet if disease exists bilateral or of the symptomatic foot, with any necessary comparison views of the contralateral uninvolved foot to allow for full evaluation of

the structural alignment and osseous morphology of the forefoot and specifically the fifth metatarsal.

Treatment Options

Nonsurgical management

Conservative treatment should be aimed toward patient education of the deformity in order to increase compliance. Proper-fitting shoe gear is essential, because many of the patient's symptoms can arise from placing increased pressure on the lateral foot and fifth metatarsal head, thus irritating the overlying skin and capsule; swelling of the fifth metatarsal bursa may also occur.^{2,5} Extra depth shoes or tennis shoes with a wider toe box can decrease direct pressure and improve symptoms. In addition, leather-style shoes may be stretched over the painful prominence by a podorthist.^{1,2,4,5,16,17}

The use of oral antiinflammatory medication and local corticosteroid injections in an inflamed bursa may reduce local tissue inflammation.^{4,17}

In cases in which the prominent metatarsal head is accompanied by hyperkeratotic lesion, debridement and padding should be performed. When pain over the fifth metatarsal head is caused by abnormal foot mechanics, prefabricated or custom orthotics may be used to alleviate symptoms and decrease pronation of the subtalar joint.

Surgical management

Operative management is warranted in patients with symptomatic bunionette deformity who have not responded to nonsurgical treatment. This management may also be the line of approach for patients with special demands, such as high-performing athletes. The procedure performed is dictated by the anatomic and biomechanical findings made during the preoperative evaluation.

The goals of surgical intervention are to decrease the width of the forefoot as well as the prominence of the bunionette. Correction of the underlying disease is necessary to prevent a recurrence of the deformity. Likewise, preservation of function of the fifth MTP joint may prevent such complications as recurrence, subluxation, dislocation, or the development of a transfer lesion.¹

Osteotomy Techniques

Operative procedures can be divided into exostectomies, resections, and various metatarsal osteotomies.² Metatarsal osteotomies can be divided based on the anatomic location: proximal, diaphyseal, or distal. Other options that have been described but are of limited usefulness are metatarsal head resection, fifth metatarsal ray resection, and isolated soft tissue procedures.

Head procedures

Lateral condyle resection Partial resection of the lateral condyle of the fifth metatarsal head is probably the most commonly used procedure. This procedure has been termed an ostectomy, exostectomy, condylectomy, or simple bunionectomy and can be performed in isolation or as part of other surgical techniques.^{6,7} It relieves the pressure symptoms and allows a slightly greater variety of shoe wear.²

The use of this technique as an isolated procedure was initially advocated by Davies in 1949.⁶ It is indicated to correct hypertrophy of the dorsal or lateral aspect of the fifth metatarsal head region without soft tissue or structural deformity and when more aggressive or involved procedures are not appropriate for the patient.⁶

Kitaoka and Holiday¹⁸ reported 15 good results, 3 fair results, and 3 poor results in 21 feet treated with lateral condylar resection for painful bunionettes. Causes of failure were inadequate resection, MTP joint subluxation, and forefoot splaying. Therefore,

the patient must be warned before surgery that only the painful bony prominence will be removed, and no other preexisting conditions such as the width of the forefoot will change with this procedure. In addition, if there is a painful callosity beneath the metatarsal head, the plantar aspect of the condyle also should be removed.²

Surgical technique⁹

- Center a longitudinal skin incision over the lateral condyle of the fifth metatarsal.
- Protect the dorsal cutaneous nerve of the fifth toe.
- Create an inverted L-type capsular incision by detaching the dorsal and proximal capsular attachments, allowing exposure of the fifth metatarsal head.
- Distract the fifth MTP joint and release the medial capsule.
- Resect the lateral eminence with an osteotome or sagittal saw.
- Close the MTP capsule by suturing it to the dorsal periosteum and to the abductor digiti quinti proximally.
- If necessary, place a suture through a drill hole in the fifth metatarsal metaphysis dorsal and lateral to ensure a stable capsular closure and prevent recurrence or lateral subluxation of the MTP joint.

Resection of fifth metatarsal head Excision of the fifth metatarsal head, resection of the distal half of the metatarsal, and fifth ray resection have all been used to treat a bunionette deformity but are not appropriate in the initial treatment of symptomatic conditions (**Fig. 10**).⁹

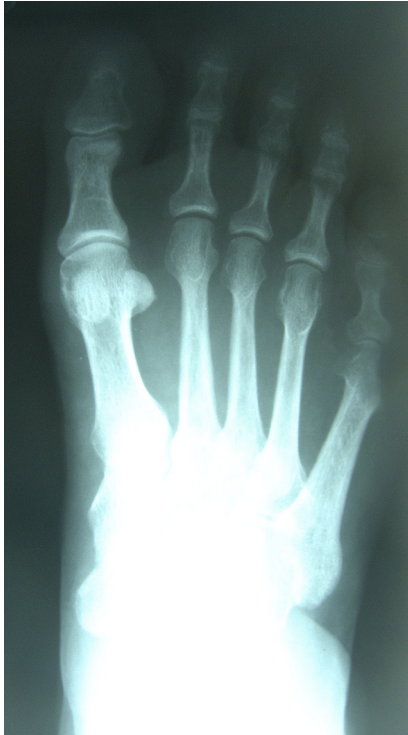

Fig. 10. AP radiograph showing a fifth metatarsal osteotomy, exostectomy, condylectomy, or simple bunionectomy. We caution that this procedure can be associated with causing a degree of instability at the fifth metatarsal phalangeal joint.

Surgical technique (Ishiwaka)

- Make a midlateral incision over the distal third of the metatarsal to expose the metatarsal head, and remove it obliquely 5 mm proximal to the capsular insertion at the head-neck junction.
- Close the capsule with absorbable sutures and the skin with nonabsorbable sutures.

Kitaoka and Holiday¹⁸ reported poor results in 7 of 11 feet with metatarsal head resection; 2 had fair results, and only 2 had good results at an average follow-up of 9 years. Causes of failure were transfer metatarsalgia, persistent lateral forefoot prominence, and painful fifth toe deformity.² These investigators did not recommend this procedure for initial operative treatment of bunionette deformity.

Dorris and Mandel¹⁹ performed a retrospective review of 50 such procedures in 34 patients for severe, recurring keratotic lesions to the plantar aspect of the fifth metatarsal head. They reported a 59% incidence of fifth digit malalignment, and Addante and colleagues^{9,20} reported malalignment and wound problems after metatarsal head resection and silicone implant arthroplasty.

Therefore, this procedure is considered unstable and is used as a salvage procedure for infection, ulceration, or severe deformity. Situations in which this procedure may be appropriate include severe osteopenia, extensive degenerative joint changes, chronic ulceration with or without osteomyelitis, previous failed surgery, or poor medical health (Fig. 11).^{6,8,9}

Distal metatarsal osteotomies

Chevron osteotomy Following the success of a stable construct for the Austin (chevron) hallux bunionectomy, many investigators such as Kitaoka used a similar technique for the bunionette deformity as well.^{16,21} In their series, these investigators reported pain relief in 15 of a total of 19 patients. Two patients required revision surgery because of severe residual pain. The 4-5 IM angle was reduced an average of 2.6°, and the MTP5 angle was reduced an average of 8° with the chevron osteotomy.

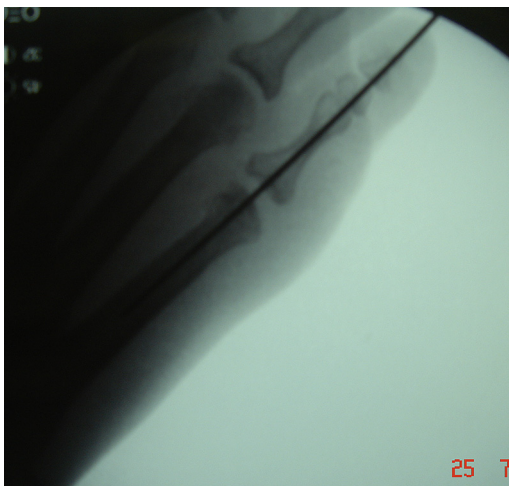

Fig. 11. An intraoperative radiograph showing a distal metatarsal resection with K-wire fixation. We caution that there is a great instability at the metatarsal phalangeal joint associated with this type of procedure.

Although the investigators believed that the osteotomy was stable, they used internal fixation with a short threaded Kirschner wire. With the dorsally directed force of weight bearing in line with the osteotomy, excess dorsal displacement is possible without internal fixation. If fixation is not performed, there may be increased risk of transfer metatarsalgia.²²

Moran and Claridge stressed that there was a low margin of error with this osteotomy and that there was a high risk for either recurrence or overcorrection. As a result, these investigators encouraged the use of Kirschner wire stabilization of the osteotomy site.^{9,22}

Surgical technique (Haskell)

- Make a midlateral longitudinal incision over the lateral eminence.
- Release the proximal and dorsal capsule using an L-type capsular incision.
- Avoid soft tissue stripping to avoid vascular insult to the distal metatarsal fragment.
- Remove about 2 mm of the lateral eminence with an osteotome or a sagittal saw.
- Mark the apex of the osteotomy with a drill hole in the midportion of the metatarsal.
- Create a horizontal chevron osteotomy with a sagittal saw. The osteotomy is based proximally with an angle of 60° and oriented in a lateral to medial direction (Fig. 12).
- Displace the distal fragment about 2 to 3 mm in a medial direction and impacted onto the proximal phalanx.
- Use Kirschner wire fixation when necessary.
- Remove any remaining prominent bone in the metaphyseal region of the fifth metatarsal with a sagittal saw.
- Reef the lateral capsule of the fifth metatarsal. If necessary, reattach the capsule through drill holes on the dorsal aspect of the metaphysis.

Distal oblique osteotomy Helal originally described the osteotomy in 1975 for treatment of intractable plantar keratosis. The osteotomy as originally described sloped in a dorsal proximal to a plantar distal direction at a 45° angle. The original description mentioned no internal fixation and immediate weight bearing.²³

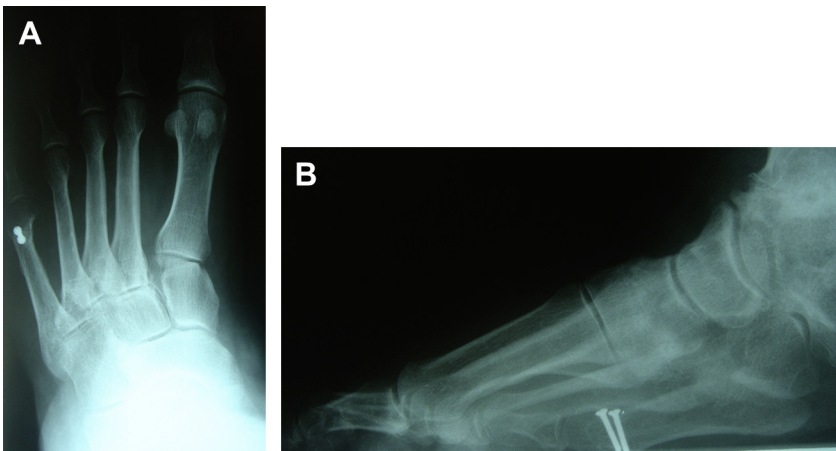


Fig. 12. (A, B) AP and lateral postoperative radiograph using a chevron osteotomy with 2 dorsal-plantar cortical screws.

According to Fiebel, Pedowitz reported one of the few positive results of the Helal osteotomy without internal fixation. A total of 41 of the 49 procedures had a good or excellent rating. Three patients had transfer lesions and 2 had nonunions, both of which were asymptomatic.

In addition, Winson and colleagues performed the metatarsal osteotomy as described by Helal. Of 124 feet, 63 had metatarsal head prominence and callosities postoperatively. Twenty-seven feet had malunions of the osteotomy site. The following factors were identified as predisposing to a poor result: patient age greater than 65 years, postoperative plaster of Paris immobilization, and poor lesser toe function.²³

Weil originally described an osteotomy that is currently popular. This osteotomy is often compared with the Helal osteotomy in the literature. However, a review of the literature shows better results with the Weil osteotomy compared with the Helal. The Weil osteotomy allows for a more predictable amount of shortening. The results have also improved with stable internal fixation. Most of the reports on the Helal osteotomy do not use internal fixation.²³

Surgical technique (Haskell)

- Make a midlateral longitudinal incision over the lateral eminence.
- Release the proximal and dorsal capsule using an L-type capsular incision.
- Release the abductor digiti quinti and resect the lateral eminence with an osteotome or sagittal saw.
- Create the oblique osteotomy of the metaphyseal neck using either a saw or an osteotome. The osteotomy is oriented in a proximal lateral to distal medial direction.
- Displace the distal fragment medially on the metatarsal and impact the bone on the proximal fragment.

Metatarsal neck osteotomy Distal fifth metatarsal head-neck osteotomies are considered efficacious for correction of mild to moderate transverse and sagittal plane deformities.^{6,7}

Hohman originally described a transverse osteotomy of the metatarsal neck. The lack of stability of this procedure increases the risk for a transfer lesion or a malunion.⁹

Metatarsal shaft osteotomies

The indications for a diaphyseal fifth metatarsal osteotomy are a bunionette deformity associated with either an increased 4-5 IM angle or lateral bowing of the distal metatarsal.⁹

Voutey carried out a transverse osteotomy in the diaphysis but described problems with rotation, angulation, and pseudarthrosis.

Oblique diaphyseal osteotomy A long, oblique, diaphyseal osteotomy of the fifth metatarsal for severe splayfoot or metatarsus quintus valgus can correct a great degree of deformity. The incidence of delayed union/nonunion is more common than with distal metaphyseal head osteotomies. However, Coughlin³ reported good or excellent results in 93% feet treated with longitudinal diaphyseal osteotomy, lateral condylectomy, and distal metatarsal joint soft tissue realignment.

Surgical technique (Coughlin)

- Make a longitudinal incision centered on the dorsolateral aspect of the fifth metatarsal extending from the base of the fifth metatarsal to the middle of the proximal phalanx. Protect the dorsolateral cutaneous nerve during dissection.

- Reflect the abductor digiti quinti muscle plantarward to expose the fifth metatarsal diaphysis. Leave the soft tissue attachments to the medial aspect intact.
- Expose the MTP joint capsule, and make an L-shaped incision along the dorsal and proximal aspects to expose the lateral eminence.
- After the capsule is detached, use a sagittal saw to resect the lateral condyle of the metatarsal head.
- Distract the MTP joint by applying distal traction to the fifth toe, and release the medial capsule of the MTP joint so that it can be realigned after the osteotomy is made.
- Use a sagittal saw to make an osteotomy in the fifth metatarsal diaphysis. For pure lateral keratosis, direct the cut from lateral to medial, with the obliquity oriented from a dorsal- proximal to a plantar distal direction. If plantar and lateral keratoses are present, angle the saw blade slightly upward to elevate the fifth metatarsal head. For a pure plantar keratosis, when more elevation of the distal fragment is desired, increase the obliquity of the osteotomy.
- Before completing the osteotomy, drill fixation holes in the proximal and distal fragments. Because the diaphysis is so narrow, placement of the holes after osteotomy can be difficult.
- Complete the osteotomy and rotate the distal fragment medially so that it is parallel with the fourth metatarsal, using the fixation hole as the axis for rotation. It is important that the osteotomy is rotated rather than translated to ensure maximal bony contact; rotation also maintains metatarsal length.
- Fix the osteotomy with a small fragment screw, screw and Kirschner wire, or multiple Kirschner wires.
- Realign the fifth toe by reefing the lateral capsule to the fifth metatarsal metaphyseal periosteum and the abductor digiti quinti. If tissue is insufficient to attach the MTP capsule, place interrupted sutures through holes drilled in the metaphysis. This capsular plication allows significant correction of axial malalignment or malrotation.

Coughlin's study reported on 30 feet that had undergone a midshaft diaphyseal metatarsal osteotomy, all of which went on to successful union. The average 4–5 IM angle was reduced 10°, and the MTP5 angle was reduced 16°. The average foot width was reduced 6 mm and no transfer lesions developed.

Vienne and colleagues reported good or excellent results in 97% of their series of patients with diaphyseal osteotomies for bunionette correction. In this study, the 4–5 IM angle was reduced from an average of 10° preoperatively to 1° postoperatively.²⁴

Castle and colleagues reported a retrospective review of 26 long oblique wedge resection osteotomies. These investigators found a mean 4–5 IM angle reduction of 1.58° (7.9°–6.48°) and a mean lateral deviation angle reduction of 3.98° (4.1°–0.28°). One osteotomy fractured after a traumatic incident in the early postoperative period, but there were no reported incidences of delayed union, malunion, or transfer lesions.²⁵

Base Osteotomy

Closing base wedge osteotomy

Proximal osteotomies are associated with a higher incidence of nonunion secondary to potential injury to the blood supply to the fifth metatarsal.⁹

Proximal fifth metatarsal base osteotomies are used to reduce increased 4–5 IM angles. The osteotomy configurations described include closing and opening base

wedges, crescent-shaped in the sagittal and transverse planes. However, the vascular supply in the proximal base region at the metaphyseal-diaphyseal junction, where the osteotomies are commonly performed, minimizes the use of this procedure.

Surgical technique (Chao)

- Use a dorsal approach to expose the metatarsal head. Make a longitudinal incision in the capsule, and debride the joint, removing loose fragments. Perform a partial synovectomy.
- Make a dorsal closing wedge osteotomy over the distal normal metaphysis, removing sufficient bone to bring the healthy plantar part of the metatarsal head into articulation with the phalanx.
- Do not remove the lesion, but rotate it proximally and dorsally.
- The angle of the closing wedge should maintain the length of the involved metatarsal bone as much as possible.
- Temporarily fix the osteotomy with crossed percutaneous Kirschner wires.

Gerbert and colleagues²⁶ described a preliminary report on the use of a closing base wedge osteotomy to the fifth metatarsal in 20 feet with favorable results.

Diebold performed a retrospective review of 22 proximal fifth metatarsal base chevron osteotomies fixated with several horizontally oriented Kirschner wires between the fifth and fourth metatarsals. There was a minimum follow-up period of 3 years. The mean 4–5 IM angle reduction was 10.88° (12.1° –1.38°), with no incidence of nonunion, malunion, or transfer lesions. The investigators concluded that the significant stability caused by transmetatarsal pinning over crossed fixation of the osteotomy was responsible for the lack of malunions and nonunions experienced in their studies.²⁷

Preferred Techniques for Tailor's Bunion

We believe the best correction for a tailor's bunion is to perform the osteotomy at the level of the deformity in the fifth metatarsal. In addition, it has been our experience that if the deformity is corrected at the appropriate site, it is not necessary to enter into the fifth metatarsal phalangeal joint. Advantages of not entering the fifth metatarsal phalangeal joint are many: maintenance of the articular surface; the fifth metatarsal phalangeal joint cannot get stiff; there is no staking of the metatarsal head; there is no instability to the fifth metatarsal phalangeal joint; and there is no neuritis associated with the procedure at the metatarsal phalangeal joint.

Distal metatarsal osteotomy

A dorsal lateral incision is made over the distal one-third of the fifth metatarsal. The incision is carried down to the bone, avoiding neurovascular structures. An oblique corrective osteotomy is made at the level of the deformity, with the base being medial and the apex being lateral. The lateral cortex is left intact, and bone resection is performed until the deformity is reduced and the metatarsal phalangeal joint is well aligned. Next, temporary fixation is applied, and a multiple-hole locking plate is applied laterally, with interfragmentary compression through the plate. A locking plate is used in cases in which we want to provide immediate weight bearing with a protective walking boot (**Fig. 13**).

Midshaft osteotomy

A dorsal lateral incision is made over the midshaft of the fifth metatarsal. The incision is carried down to the bone, avoiding neurovascular structures. An oblique corrective osteotomy is made at the level of the deformity, with the base being medial and the apex being lateral. The lateral cortex is left intact, and bone resection is performed until

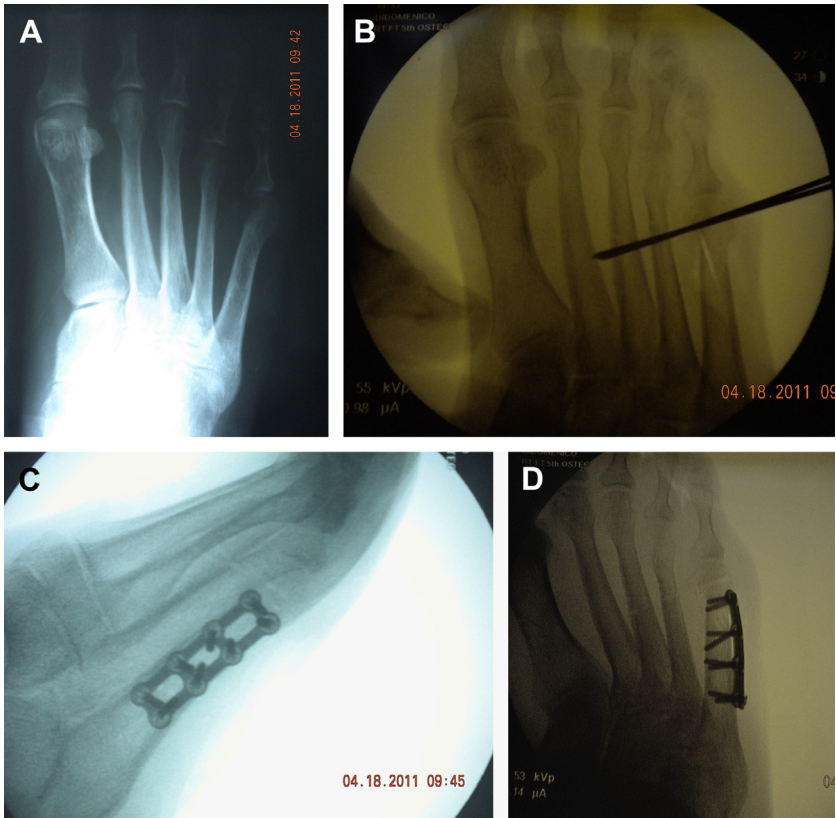


Fig. 13. (A) AP radiograph showing a tailor's bunion at the distal aspect of the fifth metatarsal. (B) An intraoperative radiograph showing the osteotomy was performed at the level of the deformity within the fifth metatarsal and temporarily reduced with K-wire fixation. (C) A lateral intraoperative radiograph showing a multiple-hole locking plate with stacked screws, providing more resistance to ground reactive forces with early weight bearing. (D) Intraoperative radiograph showing a multiple-hole locking plate. Please note that the osteotomy is reduced with an interfragmentary compression screw through the locking plate.

the deformity is reduced and the metatarsal phalangeal joint is well aligned. Next, temporary fixation is applied, and a multiple-hole locking plate is applied laterally, with interfragmentary compression through the plate. A locking plate is used in cases in which we want to provide immediate weight bearing with a protective walking boot (**Fig. 14**).

Base osteotomy

A dorsal lateral incision is made over the proximal shaft of the fifth metatarsal. The incision is carried down to the bone, avoiding neurovascular structures. An oblique corrective osteotomy is made at the level of the deformity, with the base being medial and the apex being lateral. The lateral cortex is left intact, and bone resection is performed until the deformity is reduced to the point at which the IM angle is almost parallel and the metatarsal phalangeal joint is well aligned. Next, temporary fixation is applied, and a multiple-hole locking plate is applied laterally, with interfragmentary compression through the plate. A locking plate is used in cases in which we want to provide immediate weight bearing with a protective walking boot (**Fig. 15**).

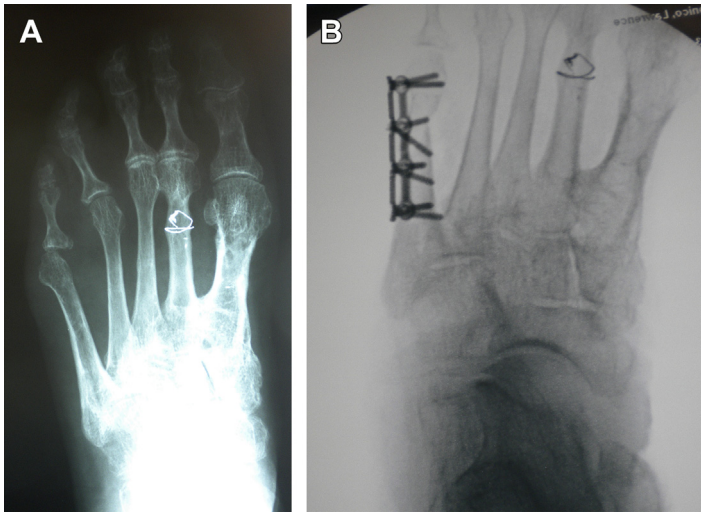


Fig. 14. (A) A preoperative AP radiograph showing a midshaft deformity with subluxation of the fifth metatarsal phalangeal joint. (B) An intraoperative radiograph showing reduction of the 4–5 IM angle. Note the metatarsal phalangeal joint reduction achieved by performing the osteotomy at the level of the deformity.

Complications

Pain and recurrence after surgical correction are mostly caused by incorrect procedure being chosen in order to address the deformity. Also, patients who underwent metatarsal head resection were more likely to experience pain sub fourth metatarsal head and concomitant underlying transfer lesion compared with other corrective procedures. Flail fifth toe may also be observed with this type of procedure, and syndactylization to the fourth digit may be required. After performing distal metatarsal procedures, subluxation of the MTP joint can occur. This complication can be avoided by tight and meticulous closure and repair of the lateral capsule.

Improper soft tissue handling and excessive soft tissue stripping can cause avascular necrosis of the metatarsal head or delayed union or nonunion at the osteotomy site. Proximal metatarsal osteotomies are at greater risk than distal osteotomies of having delayed union or nonunion because of blood supply and the unstable nature of proximal osteotomies. Delayed union is considered when an average rate of healing is not achieved for a period of 3 to 6 months.²⁸ Nonunion is established when bone union is not seen for 6 to 9 months, with no visible progression of healing for 3 months.^{28,29} This situation is typically seen when excessive motion occurs at the fracture or osteotomy site secondary to unprotected weight bearing or inadequate or poor fixation placement, which can also so lead to distraction at the osteotomy site and loss of surgical correction; malunion can result.^{30,31}

Summary

A variety of conservative treatments and surgical osteotomy procedures have been described in the literature for the bunionette deformity. We recommend making the correction at the level of the deformity and reducing the osteotomies close to normal anatomic alignment. In addition, we suggest not entering the metatarsal phalangeal joint, which should lead to a decline in complications. Utilization of locking plates allows patients to ambulate early with a protective boot.

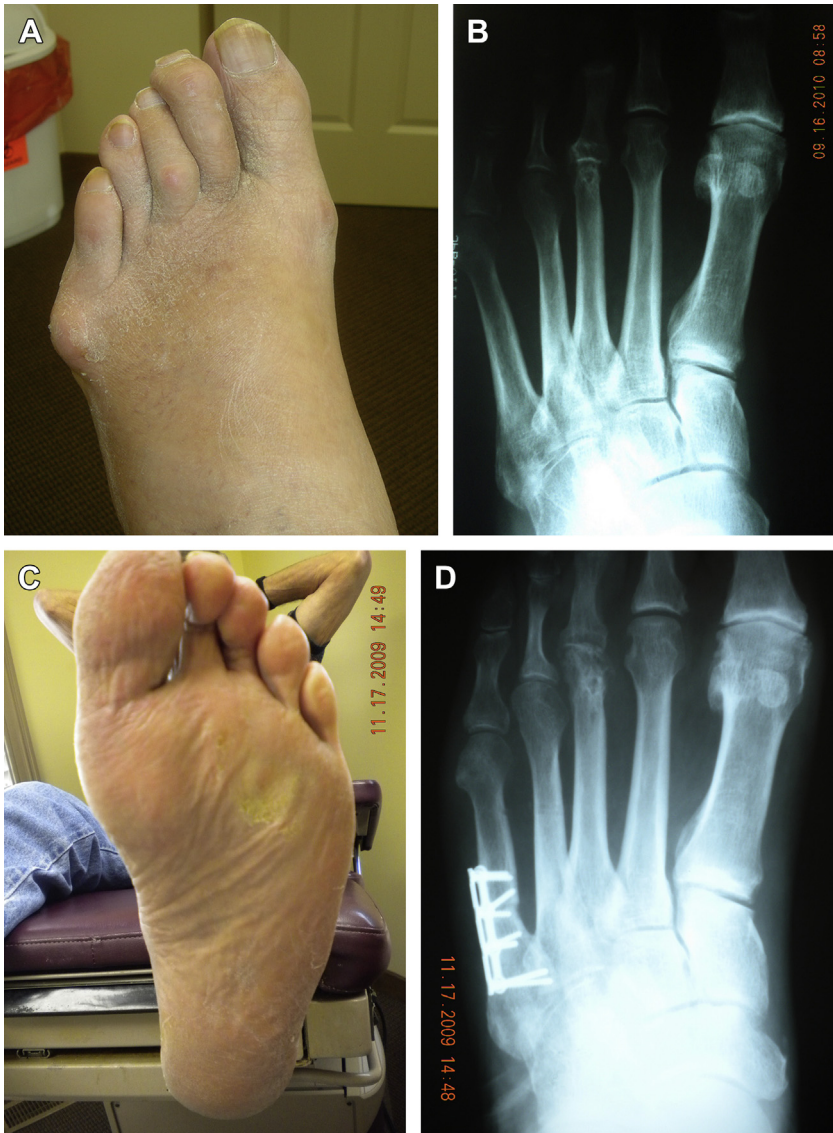

Fig. 15. (A, B) A clinical and radiographic preoperative view of a patient with a tailor's bunion with an increase in the 4-5 IM angle. (C, D) A clinical and radiograph postoperative view after a base osteotomy fixated with a multiple-hole locking plate. Note the reduction of the 4-5 IM angle.

Metatarsal osteotomies narrow the forefoot, maintain the length of the metatarsal, and preserve function of the MTP joint.²¹ Fifth metatarsal osteotomies are categorized into distal, midshaft, and base osteotomies. Distal metatarsal osteotomies produce less correction. Diaphyseal osteotomies are indicated when greater correction is needed and the 4-5 IM angle needs to be addressed. Proximal base osteotomies may be used to address significantly increased 4-5 IM angles or when a large degree of sagittal plane correction is required.

Postoperatively, early protective weight bearing, low-profile internal fixation, and protection of the surrounding soft tissue supportive structures should be used to ensure a successful outcome with minimal complications, if allowed by the level and fixation techniques.⁶⁻⁸

ADDUCTOVARUS FIFTH DIGIT

Introduction

The contracture of the digits is known as hammer toe deformity or hammer digit syndrome.^{32,33} These digital deformities can be divided into 3 types: hammer toe, claw toe, and mallet toe.^{17,32,34}

Cause

The hammer toe deformity is the most common type of digital deformity. It occurs mostly in the sagittal plane, where the MTP joint is extended, the proximal interphalangeal joint is flexed, and the distal interphalangeal joint is extended.^{32,33} Claw toe deformity is similar in appearance to hammer toe, with the exception of the flexion contracture of the distal interphalangeal joint, and mallet toe deformity is identified by flexion contracture of the distal interphalangeal joint alone.^{32,33}

The 3 main causes of hammer toe syndrome are flexor stabilization, flexor substitution, and extensor substitution. Flexor stabilization is considered the most common cause of hammer toe deformity and occurs mainly in flexible flatfoot deformity, in which there is abnormal subtalar joint pronation.^{32,35,36} It leads to unlocking of the midtarsal joint, allowing it to become hypermobile. This event allows the flexors to gain mechanical advantage over the interosseous muscles attempting to stabilize the hypermobile foot, causing reverse buckling of the digits and resulting in a contracture deformity.^{36,37} Through these events, the quadratus plantae muscle becomes less effective because of the change in direction of force caused by the flexor digitorum longus.³⁷ The pull of the flexor digitorum longus is now more proximal and medial, creating a frontal plane rotation of the digits, which gives rise to the adductovarus deformity. The fifth digit is affected more than the fourth and even the third digits because of increase in medial pull of the flexor digitorum longus tendon on the fifth digit versus the third. Peripheral neuropathy is another reason why interosseous muscles can become weakened, leading to similar digital contractures.^{32,38}

Flexor substitution is the least common cause of a hammer toe deformity. It is observed mostly in the supinated foot type, in which there is a weak triceps surae muscle. The long flexors aid in plantarflexion of the ankle, producing digital contracture because of its mechanical advantage over the interossei muscles. As this occurs, adductovarus contracture is unlikely compared with flexor stabilization, because of its supinated foot type.³²

Extensor substitution also causes digital contractures, although they mainly occur in the swing phase of gait. Extensor substitution mostly occurs in the cavus or supinated foot type, in which the extensor digitorum longus tendon gains mechanical advantage over the lumbricales.^{32,36-38} Clinically, bowstringing of the extensor tendons and claw toe digital contractures are commonly seen.

Evaluation

Clinical presentation

Patients mostly present with the main complaint of painful digital deformity.³⁹ Frontal plane rotation and adduction of the digit can be seen in addition to the contracture of the interphalangeal joints. MTP joint extension is not uncommon with adductovarus hammer toe deformity (**Fig. 16**).

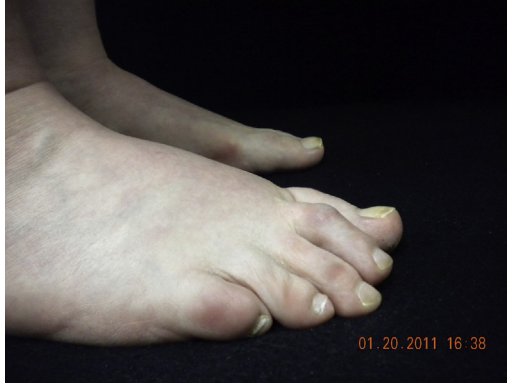

Fig. 16. A clinical view of an adductovarus deformity of the fifth digit.

Because of the rotated nature of the digit, a Lister corn in the lateral nail groove can be thick and painful.⁴⁰ Also thickening and dystrophy of the nail is common because of irritation by shoe gear. Hyperkeratotic lesions can develop from direct pressure of the bony prominences between the fourth and fifth digits.⁴⁰ A lesion can also be noted on the dorsolateral proximal interphalangeal joint caused by shoe pressure on the digit (**Fig. 17**).¹³

Radiographic evaluation

Radiographic evaluation is most commonly performed with standard AP, MO, and lateral views of the weight-bearing foot.^{12,17} Commonly, the fusion of the distal and middle phalangeal bones can be seen on all 3 views.³² Lesion markers can be used to evaluate location of painful lesions and assess the location and extent of bony deformity as well.

Physical examination

Physical examination should begin by evaluating the vascular status of the lower extremity. This examination is crucial in the decision-making process in order to attempt surgical correction. Patients with vascular compromise can also have a significant amount of pain from lack of oxygen to the digit. Ulcerations and local soft tissue

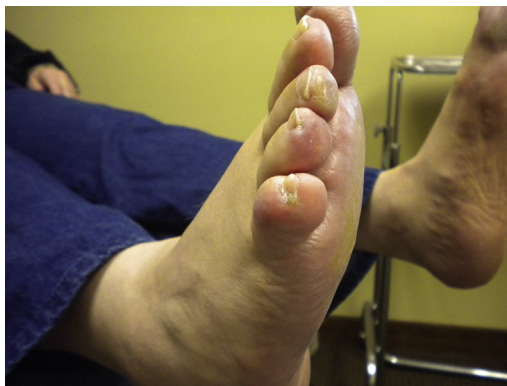

Fig. 17. A clinical view of a patient who suffers from a Lister's corn.

infection as a result of untreated hyperkeratotic lesions can complicate the outcome and change the treatment regimen.

The examiner should perform a musculoskeletal evaluation, paying close attention to any muscle group weakness or overpowering, limited joint range of motion, hypermobility of joints, and osseous foot deformity. The evaluation should also be performed while the patient is ambulating. The patient's neurologic status should also be assessed for neuropathy which can lead to intrinsic muscle weakness and produce digital deformity.

Treatment Options

Nonsurgical management

The main goal of conservative treatment of adductovarus hammer toe deformity is to decrease direct pressure and shearing forces on the digit. Initially, this goal can be achieved by wearing wider shoes with a higher toe box.^{35,39,41,42} Bony prominences and hyperkeratotic lesions can be padded with foam or gel toe sleeves. Aperture pads and toe spacers can also give pain relief and offload painful dorsal and interdigital lesions.^{13,41} Debridement of the hyperkeratotic lesions alleviates pressure and pain of the digit.⁴¹ Strengthening exercises of the intrinsic musculature can be helpful early in the deformity process by practicing grabbing small objects with the toes (**Fig. 18**).¹³

Surgical management

Condylectomy Contracture and frontal plane rotation deformity of the fifth digits can be painful in the presence of hyperkeratotic lesions overlying bony prominences. The lesions are usually present on the proximal phalanx medial or lateral as well as lateral to the distal phalanx.²⁵ Attempting to resolve the underlying pressure point may be beneficial in relieving pain.

This procedure is performed through a dorsal linear incision, and the prominent condyle or condyles are exposed and resected with bone rongeurs or power instrumentation and rasped smooth at the end.⁴⁰ This is a simple procedure with quick recovery and minimal complications.

Arthroplasty Digital arthroplasty is one of the most common procedures used to correct hammer toe deformity. It involves resection of the proximal phalangeal head, resulting in relaxation of the long flexor tendon.

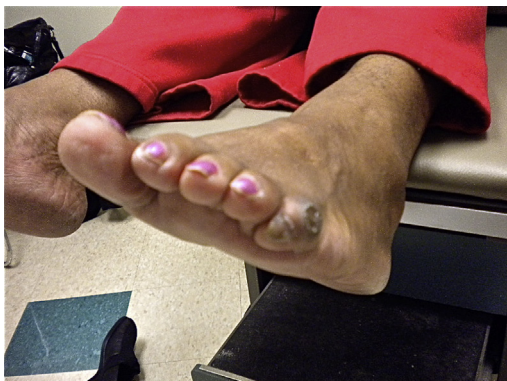

Fig. 18. A clinical view of an adductovarus fifth digit after a debridement of hyperkeratosis.

Typically, this procedure is achieved by a dorsal linear incision over the proximal interphalangeal head,⁴⁰ although it is not uncommon for the incision to be extended more proximally to gain access to the MTP joint in order to perform a capsular release of the contracted joint. In addition, an extensor hood release and Z-tendon lengthening can be performed to help reduce the contracture deformity. Kirschner wire can be used to provide stability across the interphalangeal joints as well as the metatarsophalangeal joint, maintaining correct alignment of the digit during the postoperative period.⁴⁰

The wire is usually left in place for a period of 4 to 6 weeks, allowing for fibrosis to occur, and the digit should be kept in the correct position once the wire is removed. Depending on the severity of the digital adductovarus rotation, this procedure alone may not fully correct the frontal plane deformity. A derotational skin plasty should be considered (**Fig. 19**).

Skin plasty Skin plasty of the fifth digits is a great adjunctive procedure for correction of varus or frontal plane deformity, but it is rarely used alone. Although uncommon, it can be performed solely to excise deep-seated calluses and provide substantial pain relief.

When performing a derotational skin plasty, clinical and radiographic evaluation should be performed to identify the apex of the contracture deformity so that it can be properly addressed. Most commonly, the apex of the deformity is located at the proximal interphalangeal joint, but it can also be seen at the distal interphalangeal joint, thus requiring a middle phalangectomy procedure.

The derotational skin plasty is achieved by making 2 semielliptical incisions on the dorsal aspect of the digit.⁴¹ Typically, they are obliquely oriented from distal medial and extending to proximal lateral over the proximal interphalangeal joint. The skin wedge excised can also encompass a symptomatic dorsal hyperkeratosis.^{40,31} Care should be exercised when performing the incision to avoid neurovascular structures. Once the procedure is complete, the digit is helped into the corrected position and skin closure is then performed.^{40,41}

Syndactyly Syndactyly of the fourth to fifth digits is not commonly performed as a primary procedure. Mostly, it is used in cases in which previous surgery was attempted

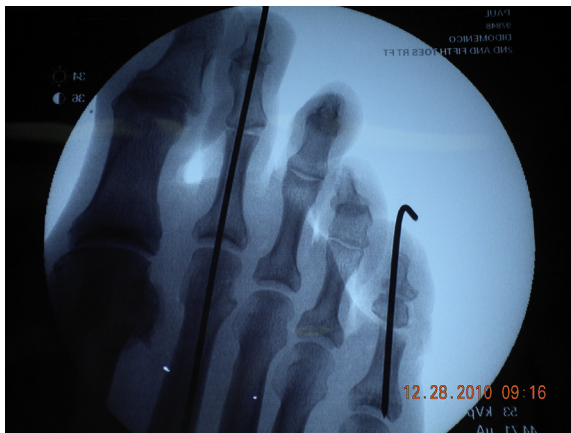


Fig. 19. An intraoperative AP radiograph after an arthroplasty of the head of the fifth proximal phalanx with K-wire fixation.

to correct the deformity but failed, leaving patients with an unstable, flail fifth digit.³⁹ It has been reported that this procedure has also been used in surgical treatment of interdigital corn.⁴⁰ The main goal is to achieve a stable fifth digit.

This goal is achieved by marking the medial side of the fifth digit and compressing the fourth and fifth toes together. The mark should leave a mirror image on the fourth toe.⁴³ Then a full-thickness skin excision is carried out. The 2 toes are sutured together and given adequate healing time.

Amputation Amputation is considered the last option when previous surgical attempts to correct the deformity have been unsuccessful.^{39,40} It is also the procedure used when surgical complications arise, such as deep infection, osteomyelitis, or gangrene.⁴⁰

Preferred Technique for Adductovarus Deformity

We recommend noninvasive vascular examination of those patients who may be at risk for vascular compromise. We have excellent experience with performing flexor digitorum longus–fifth tendon transfer as the surgical treatment of choice.

The flexor digitorum longus–fifth tendon transfer is performed as a medial approach midline incision of the fifth digit. The incision is carried deep to the deep fascia, avoiding neurovascular structures. The deep fascia tissue is incised, and the flexor digitorum longus tendon is identified. The flexor digitorum longus tendon is traced as far proximal to the web space and as far distal to its attachment on the base of the distal phalanx. The tendon is detached from the base of the distal phalanx, allowing the adductor pull and flexor contracture to be released. The flexor digitorum brevis (both the medial and lateral heads) is detached from the base of the middle phalanx. This procedure also reduces any remaining flexion contracture. Next, if necessary, a capsulotomy is performed at the proximal or distal interphalangeal joint to obtain a full reduction of any remaining contracture. A 15.75-mm (0.62-inch) K-wire is inserted from the distal phalanx through the distal and proximal interphalangeal joint, ensuring complete reduction of the flexor and adductor contracture. With the fifth digit in the desired position, the flexor digitorum longus tendon is then transferred to the extensor hood on the medial dorsal aspect of the fifth toe. The toe is put into the desired anatomic position and physiologic tension is applied to the tendon as it is sutured

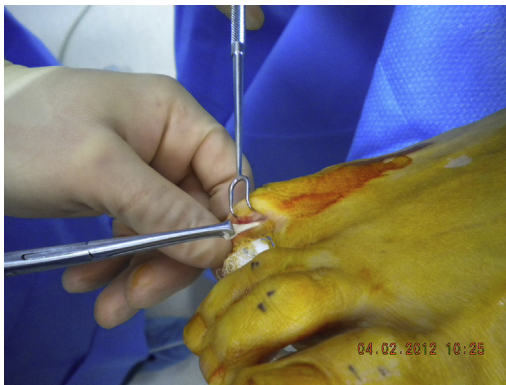

Fig. 20. The fifth flexor digitorum longus tendon is released from the midline medial incision. A gauze sponge is used to wrap around the fourth digit to retract it from the surgical field.

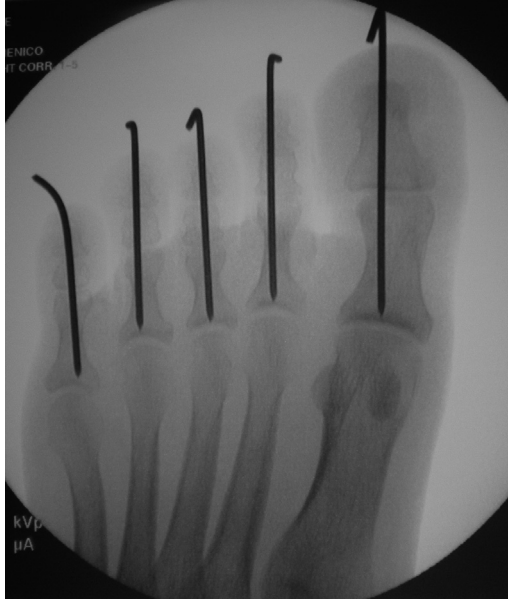

Fig. 21. An intraoperative photograph after flexor digitorum longus tendon transfer performed for adductovarus deformity of a fifth toe as well as flexor contractures of digits 1 to 5.

to the extensor hood. The skin is closed in typical fashion. The K-wire is removed in 7 days, and the sutures are removed at 14 days.

We have experienced advantages such as less postoperative edema, the length of time the K-wire fixation is needed, surgical cosmesis (medial interdigital incision), and the surgical procedure addressed the underlying disease, and therefore there is no reoccurrence or flail toe (**Figs. 20** and **21**).

Complications

Patients may experience prolonged swelling, which can be unattractive, especially for women. Recurrent painful lesion and deformity of the digits such as flail toe, misalignment, and loss of digital purchase can also be seen and may require additional surgery.^{33,39–41,43,44}

Summary

Correction of the fifth digit deformity for a foot and ankle surgeon can be rewarding as well as challenging. Immense care should be taken when performing any digital procedure, especially of the fifth digits, to avoid and minimize complication rates and mainly to prevent neurovascular damage.

REFERENCES

1. Bertrand T, Selene GP. Bunionette deformity: etiology, nonsurgical management, and lateral exostectomy. *Foot Ankle Clin* 2011;16:679–88.
2. Ishikawa SN, Murphy GA. Lesser toe abnormalities. In: Canale ST, editor. *Campbell's operative orthopaedics*. 10th edition. Philadelphia, PA: Mosby; 2003. p. 4652–60.

3. Coughlin MJ. Treatment of bunionette deformity with longitudinal diaphyseal osteotomy with distal soft tissue repair. *Foot Ankle* 1991;11:195.
4. Ajs A, Koti M, Maffulli N, et al. Taylor's bunion: a review. *J Foot Ankle Surg* 2005;44:236–45.
5. Wexler D, Grosser DM, Kile TA. Bunion and bunionette. In: Frontera WR, Silver JK, editors. *Essentials of Physical Medicine and Rehabilitation*. 2nd edition. Philadelphia, PA: Saunders Elsevier; 2008;chap 76.
6. Roukis TS. The tailor's bunionette deformity: a field guide to surgical correction. *Clin Podiatr Med Surg* 2005;22:223–45.
7. Roukis TS. Minimum-incision metatarsal osteotomies. *Clin Podiatr Med Surg* 2008;25:587–607.
8. Roukis TS. Central metatarsal head-neck osteotomies: indications and operative techniques. *Clin Podiatr Med Surg* 2005;22:197–222.
9. Haskell A, Mann RA. Foot and ankle. Biomechanics. In: DeLee JC, Drez D Jr, Miller MD, editors. *DeLee & Drez's orthopaedic sports medicine*, vol. 2, 3rd edition. Philadelphia: Saunders/Elsevier; 2010. p. 1865–73.
10. Baumhauer JF, Benedict FD. Osteotomies of the fifth metatarsal. *Foot Ankle Clin* 2001;6:3.
11. Hansen ST. *Functional reconstruction of the foot and ankle*. 1st edition. Philadelphia: Lippincott Williams & Wilkins; 2000. p. 264.
12. Good J, Fiala K. Digital surgery: current trends and techniques. *Clin Podiatr Med Surg* 2010;27:583–99.
13. Caselli MA, George DH. Foot deformities: biomechanical and pathomechanical changes associated with aging, part I. *Clin Podiatr Med Surg* 2003;20:487–509.
14. Fallat L, Buckholz J. An analysis of the tailors bunion by radiographic and anatomic display. *J Am Podiatry Assoc* 1980;70:597.
15. Casteel CA, Sikorski A, De Yoe BE. Surgery of the central rays. *Clin Podiatr Med Surg* 2010;27:509–22.
16. Pontious J, Lane GD, Moritz JC, et al. Lesser metatarsal V-osteotomy for chronic intractable plantar keratosis: retrospective analysis of 40 procedures. *J Am Podiatr Med Assoc* 1998;88:323–31.
17. Thomas JL, Blich EL 4th, Chaney DM, et al. Diagnosis and treatment of forefoot disorders. Section 1: digital deformities. *J Foot Ankle Surg* 2009;48(2):230–72.
18. Kitaoka HB, Holiday AD. Lateral condylar resection for bunionette. *Clin Orthop* 1992;278:183–92.
19. Dorris MF, Mandel LM. Fifth metatarsal head resection for correction of tailor's bunions and sub-fifth metatarsal head keratoma: a retrospective analysis. *J Foot Surg* 1991;30(3):269–75.
20. Addante JB, Chin M, Makower BL, et al. Surgical correction of tailor's bunion with resection of fifth metatarsal head and Silastic sphere implant: an 8-year follow-up study. *J Foot Surg* 1986;25(4):315–20.
21. Weil L, Weil LS. Osteotomies for bunionette deformity. *Foot Ankle Clin* 2011;16:689–712.
22. Schuh R, Trnka HJ. Metatarsalgia: distal metatarsal osteotomies. *Foot Ankle Clin* 2011;16:583–95.
23. Helal B. Metatarsal osteotomy for metatarsalgia. *J Bone Joint Surg Br* 1975;57:187–92.
24. Vienne P, Oesselmann M, Espinosa N, et al. Modified Coughlin procedure for surgical treatment of symptomatic tailor's bunion: a prospective follow-up study of 33 consecutive operations. *Foot Ankle Int* 2006;27:573–80.

25. Castle JE, Cohen AH, Docks G. Fifth metatarsal distal oblique wedge osteotomy utilizing cortical screw fixation. *J Foot Surg* 1992;31:478–85.
26. Gerbert J, Sgarlato TE, Subotnick SI. Preliminary study of a closing wedge osteotomy of the fifth metatarsal for correction of a tailor's bunion deformity. *J Am Podiatr Assoc* 1972;62(6):212–8.
27. Diebold PF, Bejjani FJ. Basal osteotomy of the fifth metatarsal with intermetatarsal pinning: a new approach to the tailor's bunion. *Foot Ankle* 1987;8(1):40–5.
28. LaVelle DG. Delayed union and nonunion of fractures. In: Canale ST, editor. *Campbell's Operative Orthopedics*. 10th edition. Vol. 3. Philadelphia, PA: Mosby; 2003. p. 3125–65.
29. Dolce M, Adamov DJ. Postoperative complication in podiatric surgery. In: Levy LA, Hetherington VJ, editors. *Principles and practice of podiatric medicine*, vol. 51. Brooklandville (MD): Data Trace; 2006. p. 1–14.
30. Bellacosa RA, Pollak RA. Complications of lesser metatarsal surgery. *Clin Podiatr Med Surg* 1991;8(2):383–97.
31. Coughlin MJ. Bunionettes. In: Coughlin MJ, Mann RA, Saltzman CL, editors. *Surgery of the foot and ankle*. 8th edition. Philadelphia: Mosby-Elsevier; 2007. p. 491–530.
32. McGlamry ED, Jimenez AL, Green DR. Part 1: deformities of the intermediate digits and the metatarsophalangeal joint. In: Banks AS, Downey MS, Martin DE, et al, editors. *McGlamry's comprehensive textbook of foot and ankle surgery*. Philadelphia: Lippincott, Williams & Wilkins; 2001. p. 253–304.
33. Mandracchia VJ, Mandi DM, Haverstock BD, et al. Lesser metatarsal and digital surgery. In: Levy LA, Hetherington VJ, editors. *Principles and practice of podiatric medicine*, vol. 41. Brooklandville (MD): Data Trace; 2006. p. 1–46.
34. Harmonson JK, Harkless LB. Operative procedures for the correction of hammertoe, claw toe, and mallet toe: a literature review. *Clin Podiatr Med Surg* 1996;13(2):211–20.
35. Coughlin MJ. Lesser toe deformities. In: Coughlin MJ, Mann RA, Saltzman CL, editors. *Surgery of the foot and ankle*. Philadelphia: Mosby; 2007. p. 363–464.
36. Green DR, Brekke M. Anatomy, biomechanics, and pathomechanics of lesser digital deformities. *Clin Podiatr Med Surg* 1996;13(2):179–200.
37. Spencer SA. Pathomechanics of common foot pathologies. In: Levy LA, Hetherington VJ, editors. *Principles and practice of podiatric medicine*, vol. 4. Brooklandville (MD): Data Trace; 2006. p. 1–10.
38. DiDomenico L. Essential insight on the tendon transfers for digital dysfunction. *Podiatry Today* 2010;23(4):44–55.
39. Coughlin MJ. Lesser-toe abnormalities. *Instr Course Lect* 2002;84(8):1445–69.
40. Smith TF, Pfeifer KD. Part 2: surgical repair of fifth digit deformities. In: Banks AS, Downey MS, Martin DE, et al, editors. *McGlamry's comprehensive textbook of foot and ankle surgery*. Philadelphia: Lippincott, Williams & Wilkins; 2001. p. 305–21.
41. Strash WW. Arthroplasty for fifth toe deformity. *Clin Podiatr Med Surg* 2000;27:625–8.
42. Marek L, Giacopelli J, Granoff D. Syndactylization for the treatment of fifth toe deformities. *J Am Podiatry Assoc* 1991;81(5):248–52.
43. Weil L, Schilling RA. How to handle complications of hammertoe surgery. *Podiatry Today* 2005;18(9):1–5.
44. Coughlin MJ, Dorris J, Polk E. Operative repair of the fixed hammertoe deformity. *Foot Ankle Int* 2000;21(2):94–104.